

**Qasimov E.K.**

## **XÜSUSİ HİSTOLOGİYA**

**Sxemlər**

**Azərbaycan Tibb Universitetinin Elmi Şurasının 30 oktyabr  
2018-ci il tarixli iclasında dərs vəsaiti kimi dərc olunması  
qərara alınmışdır**

**Bakı 2019**

***Rəyçilər:***

Azərbaycan Tibb Universitetinin Histologiya, embriologiya və sitologiya kafedrasının dosenti, t.ü.f.d. **M.R. Mehtiyev** və həmin kafedranın assistenti t.ü.f.d. **A.Ə. Əliyərbəyova**

Azərbaycan Tibb Universitetinin İnsan Anatomiyası kafedrasının professoru, t.ü.e.d. **A.B. İsayev**

Bakı Dövlət Universitetinin Genetika və Təkamül təlimi kafedrasının dosenti, b.ü.f.d. **Ə.Ə. Səmədov**

Qasımov E.K. Xüsusi histologiya. Sxemlər). Bakı. 2019. 110 səh.

Dərs vəsaiti tibb ixtisası üzrə təhsil alan ali və orta-ixtisas məktəblərin tələbələri üçün nəzərdə tutulmuşdur. Bununla birlikdə biologiya fakültəsinin tələbələri, həmçinin histoloqlar da istifadə edə bilirlər.

## ÖN SÖZ

Son illər respublikamızın təhsil sistemində aparılan islahatlar, xüsusilə Avropa vahid təhsil ailəsinə inteqrasiya yönündə atılan ciddi addımlar bizim də qarşımızda vacib öhdəliklər qoyur. Əsas tibb fənlərindən biri olan histologiyanın tədrisini günün tələbləri səviyyəsində qurmaq üçün klassik məlumatlarla yanaşı, müasir elmi biliklərin toplanması və tələbələrə çatdırılması çox zəruridir.

Bu baxımdan tərtib edilmiş «Xüsusi histologiya – sxemlər» adlı dərs vəsaiti orqan və sistemlərin mikroskopik quruluşlarının daha dərin və mükəmməl mənimsənilməsində tələbələrə yardımçı olmalıdır. Tələbələr sxemlərdəki strukturları dərs vəsaitinin elektron variantına müvafiq olaraq rəngləməli və onların adlarını sol tərəfdə ayrılmış boş yerdə yazmalıdırlar.

Dərs vəsaitinə daxil edilmiş sxemlərin böyük əksəriyyəti tədris proqramında nəzərdə tutulmuş preparatlara uyğun çəkilmişdir. Ona görə də tələbələr dərs prosesi zamanı öyrənilən histoloji mikropreparatlara bilavasitə mikroskopun müxtəlif böyüdücülərində baxmaqla yanaşı, onların sxemlərinin miqyasının kompüterdə artırılıb - azalma imkanlarına da malik olacaqlar. Bu isə keçirilən materialın tələbələr tərəfindən mənimsənilməsini xeyli asanlaşdırmalıdır.

Müəllif istifadə olunmuş ədəbiyyat materiallarının (adları ədəbiyyat siyahısında verilmişdir) müəlliflərinə, sxemlərin çəkilməsində iştirak edən tələbələrimizə və albomun tərtibində köməklik etdiklərinə görə assistent A.Ə.Əliyarbəyova, N.T. Quliyevaya və laborant V.M.Hüseynovaya öz dərin minnətdarlığını bildirir.

Dərs vəsaitinin tərtibində buraxılmış xətalara görə əvvəlcədən üzr istəyir və bu haqda məlumat verənlərə öz minnətdarlığımı bildirirəm.

*Müəllif*

## XÜSUSİ MİNNƏTDARLIQ

Verilən materialların informasiya yükünün artırılması və tədris olunan materiallara aid inkişaf etmiş ölkələrdə nəşr olunmuş dərsliklərdə olan yeni məlumatların tələbələr tərəfindən mənimsənilməsi üçün dərc olunan alboma internet resurslarında olan bəzi sxematik şəkillər də daxil edilməsidir. Qəbul olunmuş qaydalara görə istifadə olunan materialların müəlliflərindən icazə alınmalıdır.

Bu məqsədlə bizi maraqlandıran məlumatlar olan internet resurslarının hamısı ilə yazışmalar aparan zaman onların bəzilərinin heç bir tələb qoymadan öz materiallarından istifadə olunmasına icazə vermələri müasir kommersiya əlaqələrinin artdığı bir dövrdə möcüzə olsa da bunu təsdiq olunmuş bir fakt kimi qəbul etmək məcburiyyətindəyik.

Müraciət olunmuş müəlliflər arasında xüsusi olaraq ABŞ-ın Vircinya-Marilend təbib baytarlıq kollecinin professoru Thomas Cacecini qeyd etmək lazımdır. Professorun beynəlxalq səviyyədə tədrisin səviyyəsinin artırılmasına olan marağının təsdiqi kimi onun özünün bizim müraciətimizə cavabını olduğu kimi vermək məsləhətdir: ” Dear Dr. Gasimov: By all means, please feel free to use the pictures. I am happy that you find my work suitable for your educational purposes.”

İnternet resurslar arasında ABŞ Texas ştatının Hyuston şəhərində yerləşən Rise Universitetinin dərc etdirdiyi “Anatomy & Physiology” dərsliyində olan sxemlərin azad olaraq “Vikipediya”ya daxil edilməsi və Türkiyənin Hacettepe Universitetinin Tibb fakültəsinin histologiya kafedrası əməkdaşları tərəfindən tərtib olunmuş “Histology Drawings” saytında verilən materiallardan azad istifadəsinə icazə vermələri minnətdarlıqla qəbul olunmalıdır. Maraqlısı odur ki, adı çəkilən

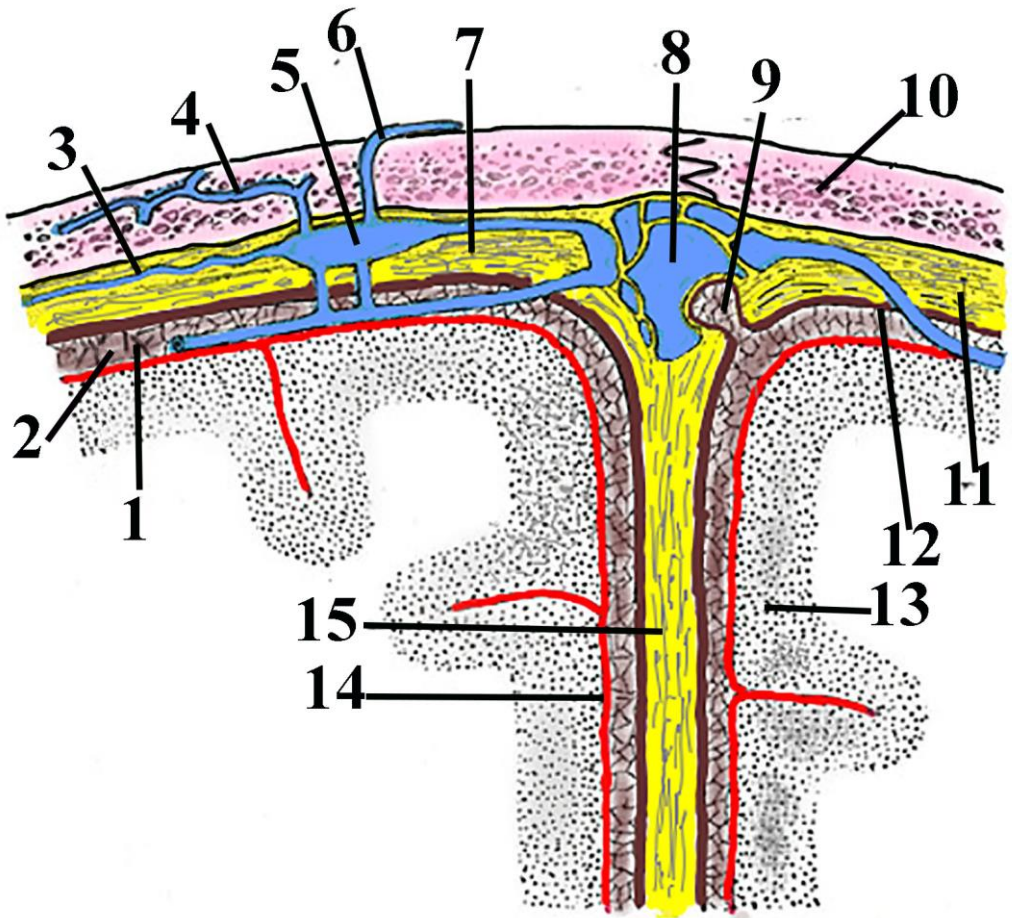


resurslarda və internetə daxil edilmiş digər sxemlərdə olan yeni bir məlumat mənim tərəfindən çəkilmiş sxemlərin müasir informasiya yükünün xeyli artırılmasının əsas səbəbi olmuşdur.

Qeyd etməyi özümə borc bilərəm ki, mənim özüm tərəfindən çəkilmiş sxemlər yaxın zaman ərzində azad istifadə olunması üçün Vikipediya daxil ediləcəkdir.

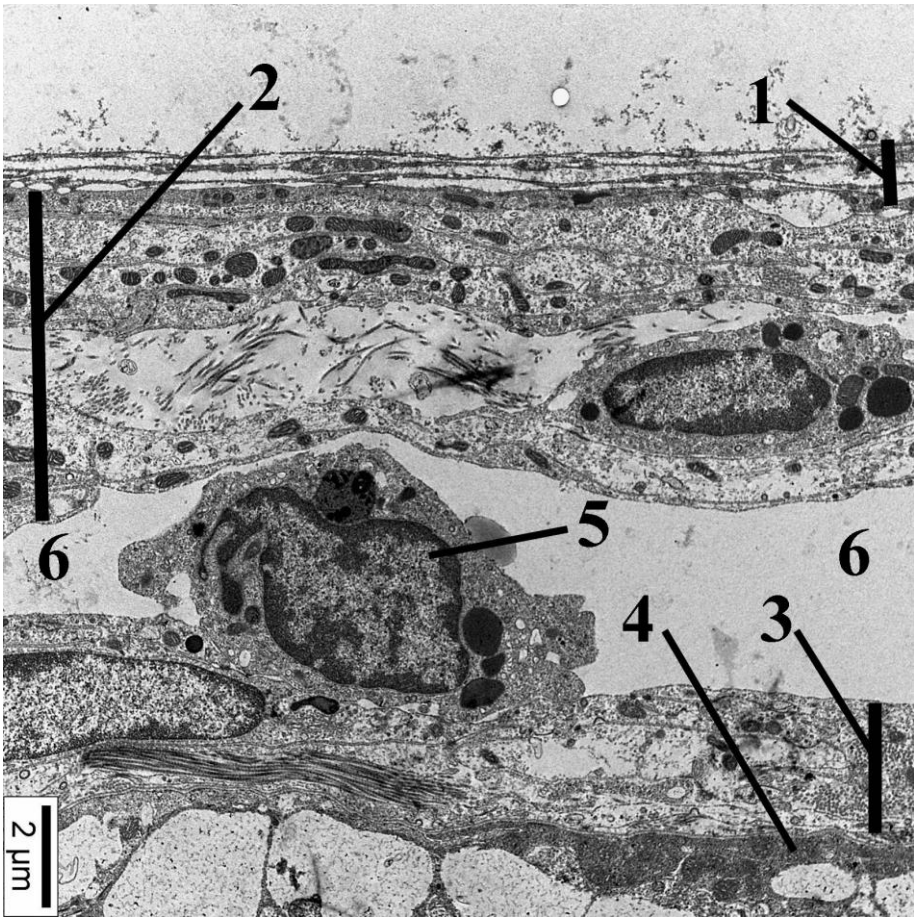
Yekun olaraq bu albomun tərtib olunmasında istifadə olunmuş informasiyaların müəlliflərinin hər birinə bir daha minnətdarlığımı bildirirəm.

*Müəllif*



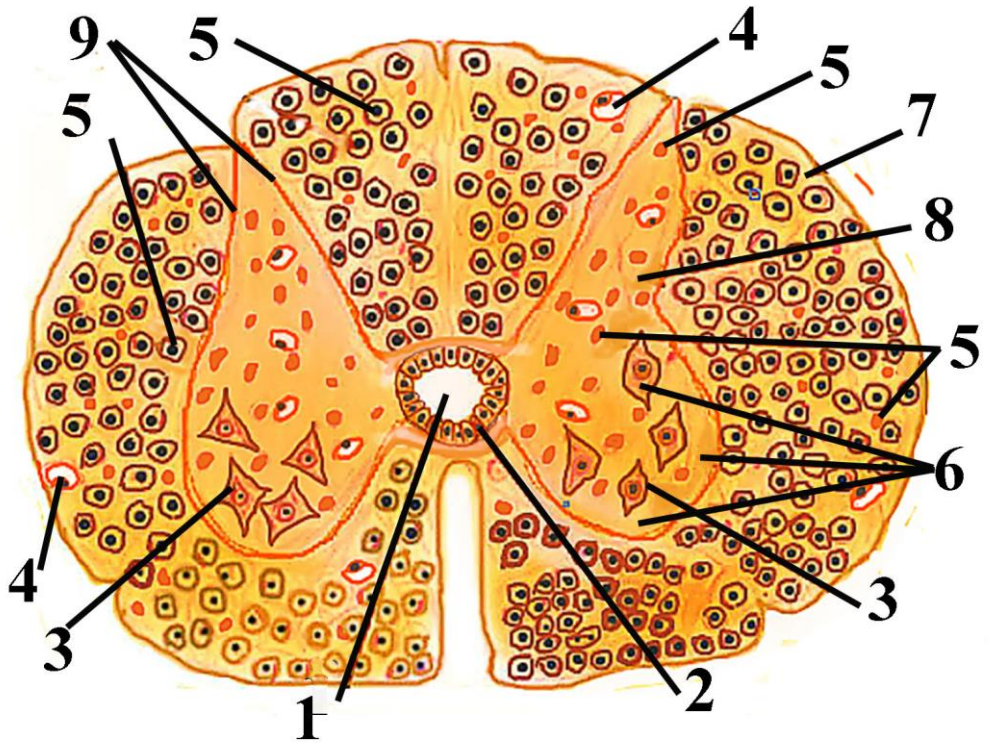
**Fig. 1.1 Interrelations between skull, sinuses of dura mater and brain cortex.**

1.Trabecules of arachnoid matter; 2. Subarachnoid space; 3. Dural vein; 4. Diploic vein; 5. Dural sinus; 6. Emissural vein; 7 and 11 dura mater; 8. Superior sagittal sinus; 9. Pachionian granulation; 10. Bone of skull; 12. Arachnoid matter; 13. Brain cortex; 14. Pia mater; 15. Falx cerebri.



**Figure 1.2. Electron microscopic structure of cellular and noncellular elements of meninges.**

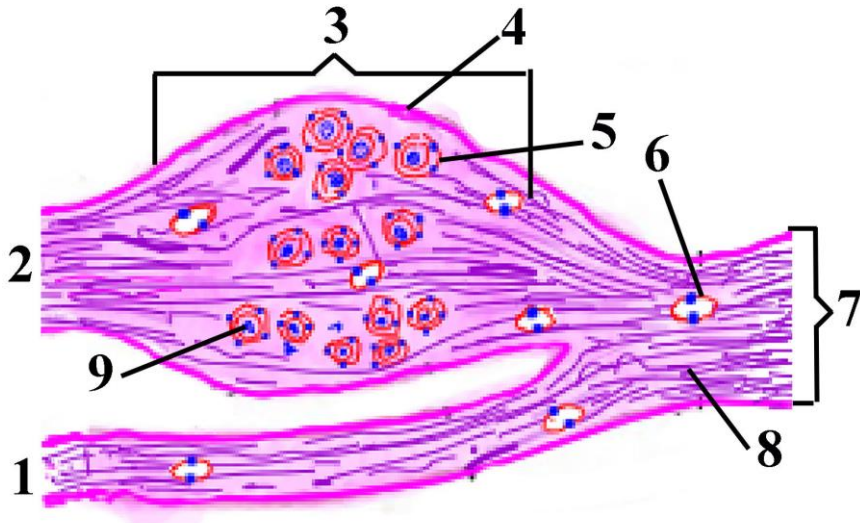
1. Dura mater; 2. Arachnoid mater; 3. Pia mater; 4. Glia limitans; 5. Macrophage in subarachnoid space; 6. Subarachnoid space.



**Figure 1.3. Cross section of spinal cord.**

Central canal; 2. Ependymal cell; 3. Motor neurons of anterior horn; 4. Blood vessels; 5. Glial cells (on the right side) and 5. nerve fibers (on the left side); 6. Anterior horn; 7. White matter of the spinal cord; 8. Grey matter; 9. Posterior horn.

Dorsal root ganglion. The structure of the peripheral nerve. Vegetative nervous system.



Şəkil 2.1.

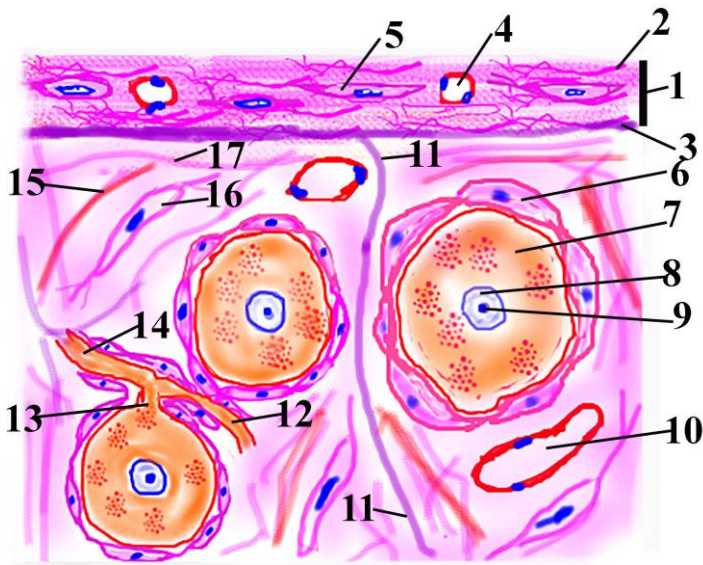
Рисунок 2.1.

Figure 2.1.

**Spinal ganglion (sensory ganglion) and surrounding structures.**

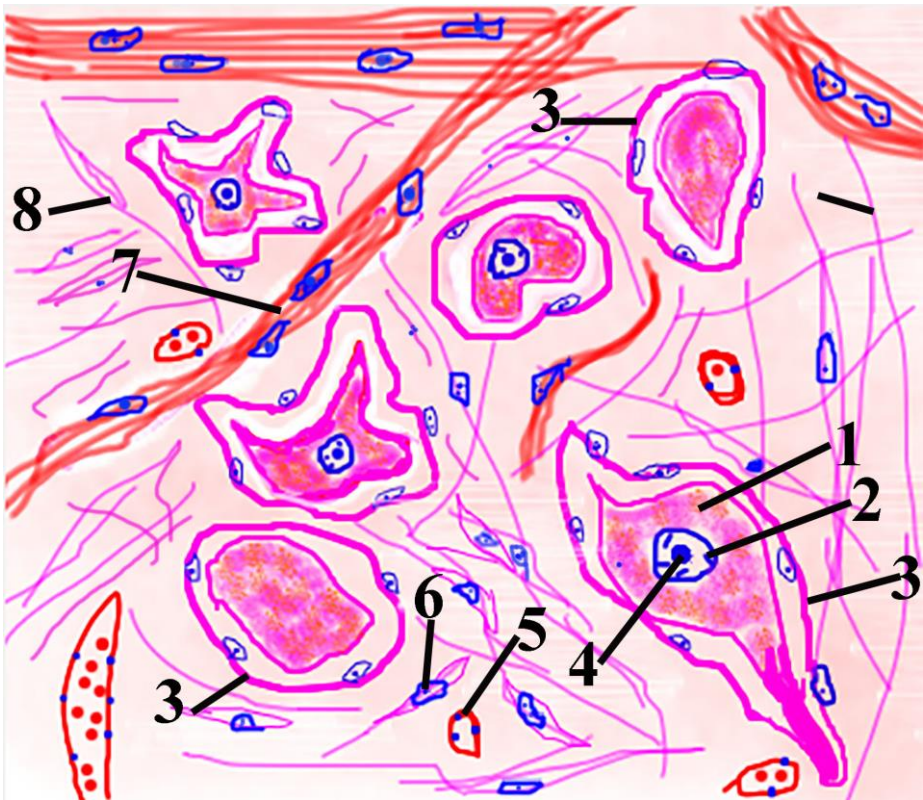1. Anterior root; 2. Posterior root; 3. Spinal ganglion; 4. Capsule;  
 5. Satellite cell; 6. Blood vessel; 7. Spinal nerve; 8. Nerve fiber;  
 9. Cell bodies of pseudounipolar neurons.





**Şəkil 2.2.                      Рисунок 2.2.                      Figure 2.2.**  
**Histotopography of neurons, nerve fibers, glial cells and connective tissue elements in spinal ganglion.**

1.Capsule of spinal ganglion; 2. Connective tissue elements; 3. perineural cells of capsule; 4. Blood vessel of capsule; 5. Fibrocyte of capsule; 6. Satellite cell; 7. Pericaryon of pseudounipolar neuron; 8. Nucleus of of pseudounipolar neuron; 9. Nucleolus of pseudounipolar neuron; 10. Blood vessel inside of capsular trabecule; 11. Capsular trabecule; 12. Peripheral process of pseudounipolar neuron; 13. Initial part of process of pseudounipolar neuron; 14. Central process of pseudounipolar neuron; 15. Elastic fiber; 16. Fibrocyte inside of capsular trabecule; 17. Bundle of collagen fibers.



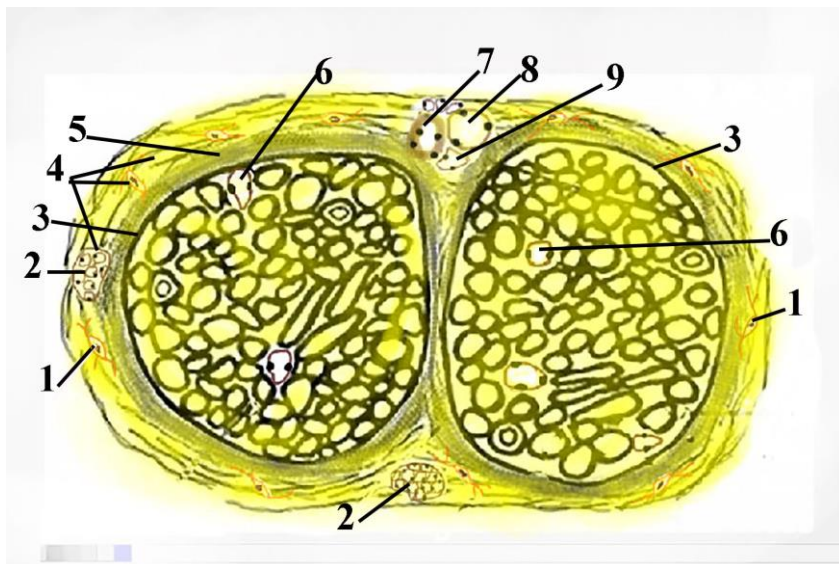
Şəkil 2.3.

Рисунок 2.3.

Figure 2.3.

**Histotopography of neurons, nerve fibers, glial cells and connective tissue elements inside of sympathetic ganglion.**

1.cell body of multipolar neuron; 2. Nucleus of multipolar neuron; 3. Satellite cell; 4. Nucleolus of multipolar neuron; 5. Blood vessel; 6. Fibrocyte; 7. Nerve fibers; 8. Bundle of collagen fibers.



Şəkil 2.4.

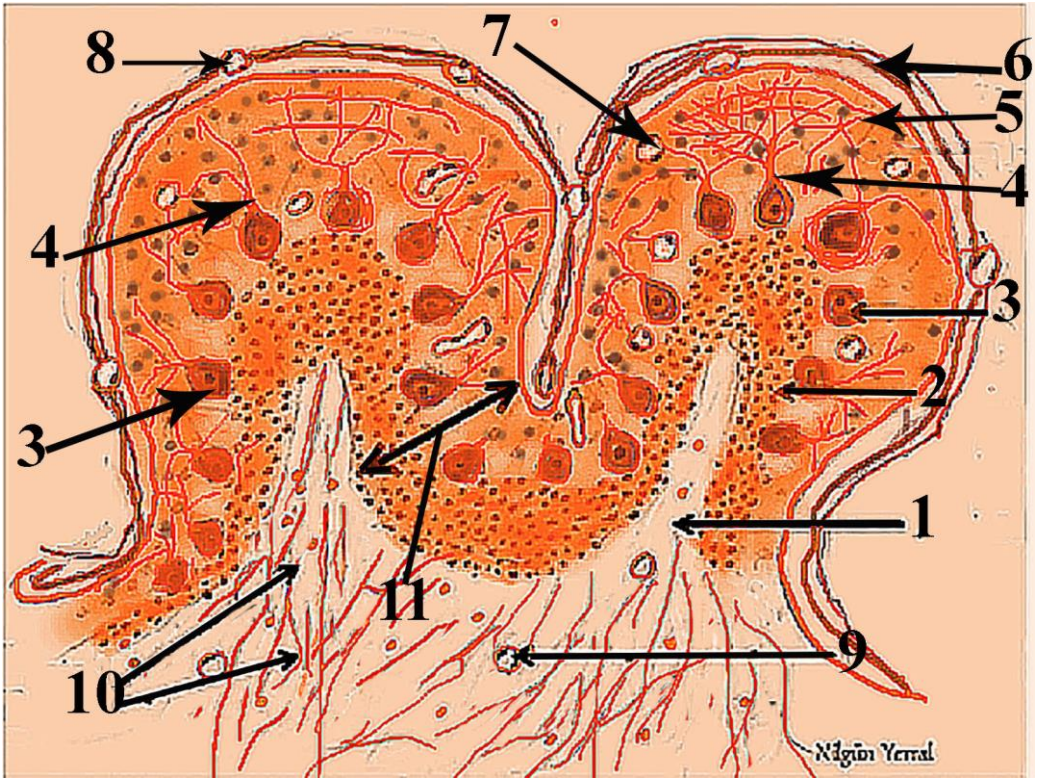
Рисунок 2.4.

Figure 2.4.

**Cross section of peripheral nerve trunk.**

1. Fibrocyte; 2. Accumulation of fat cells; 3. Perineurium; 4. Loose connective tissue of epineurium that surround nerve trunk; 5. Part of epineurium that surround bundle of nerve fibers; 6. Capillary of endoneurium; 7. Arteriole of epineurium; 8. Venule of epineurium; 9. lymphatic capillary of epineurium.





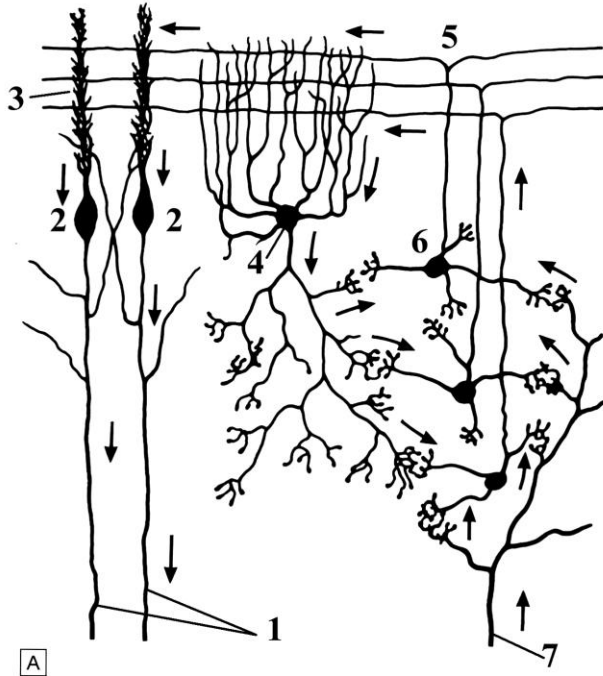
Şəkil 3.1.

Рисунок 3.1.

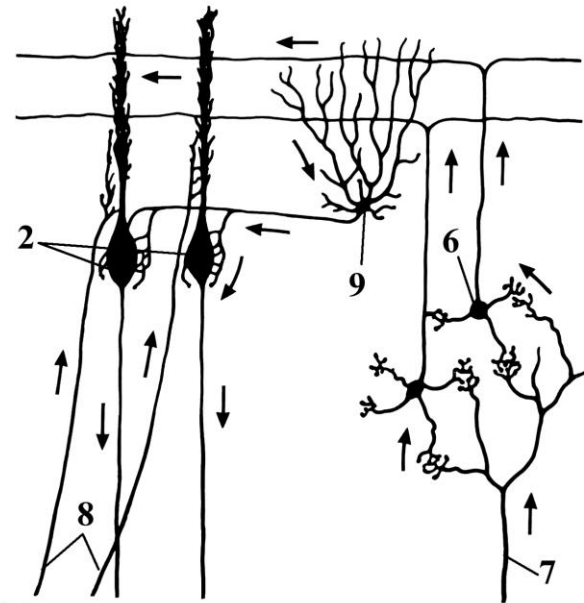
Figure 3.1.

**Microscopic structure of cerebellum.**

1. White matter of cerebellum; 2. Granular layer; 3. Layer of Purkinje cells, 4. Dendrite of Purkinje cells; 5. Molecular layer, 6. Pia mater; 7. Blood vessel of cerebellar cortex, 8. Blood vessel of pia mater, 9. Capillary in white matter, 10. Nerve fibers, 11. Cerebellar cortex.



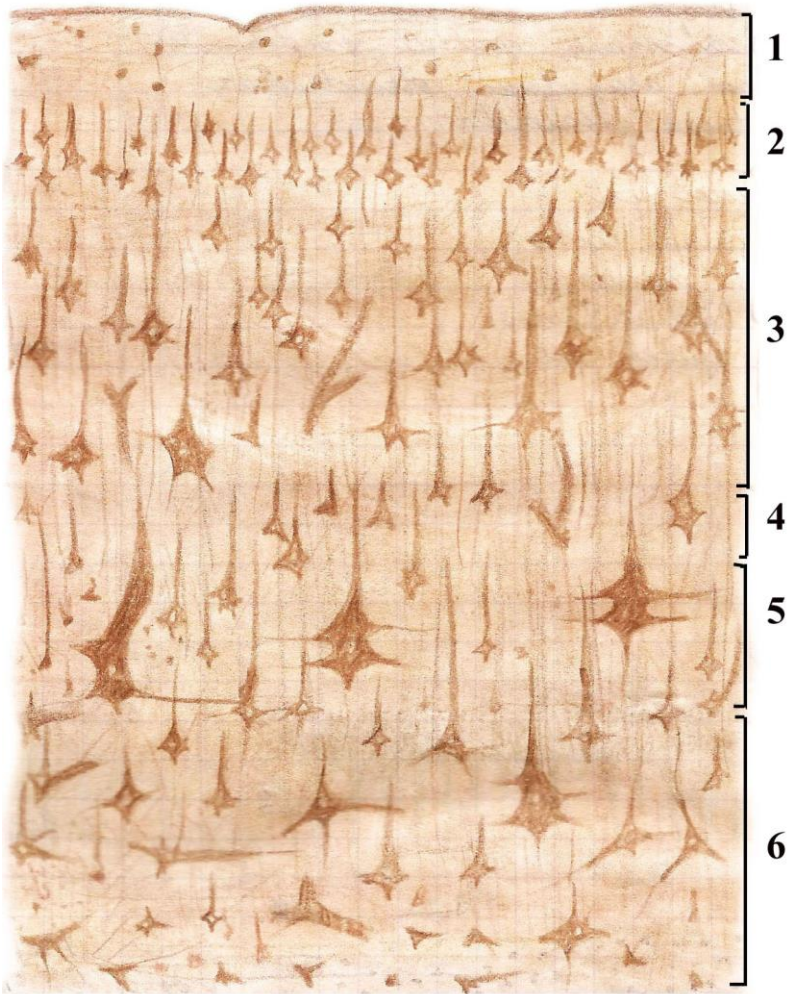
A



B

**Şəkil 3.2.                    Рисунок 3.2.                    Figure 3.2.**  
**Schematic representation of interneuronal relations in the cerebellar cortex. Arrows indicate the direction of nerve impulse passing.**

1. axons of Purkinje cells
2. Purkinje cells
3. relations between dendrite of Purkinje cells with axon of granule cell
4. Golgi cell
5. parallel fibers
6. granule cell
7. mossing fibers
8. climbing fibers
9. basket cell




Şəkil 4.1.

Рисунок 4.1.

Figure 4.1.

**Schematic structure of cerebral cortex.  
Silver impregnation: Cajal's method.**

1. Molecular layer
2. External granular layer
3. External pyramidal layer
4. Internal granular layer
5. Internal pyramidal layer
6. Multimorph cell layer



Şəkil 4.2.

Рисунок 4.2.

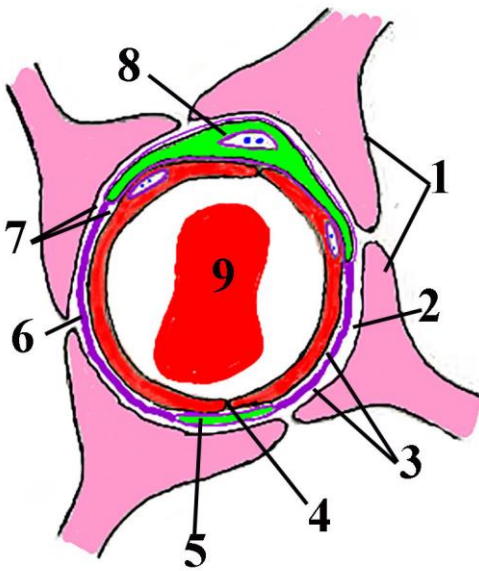
Figure 4.2.

**Interrelations between prevalent neurons and nerve fibers inside of brain cortex.**

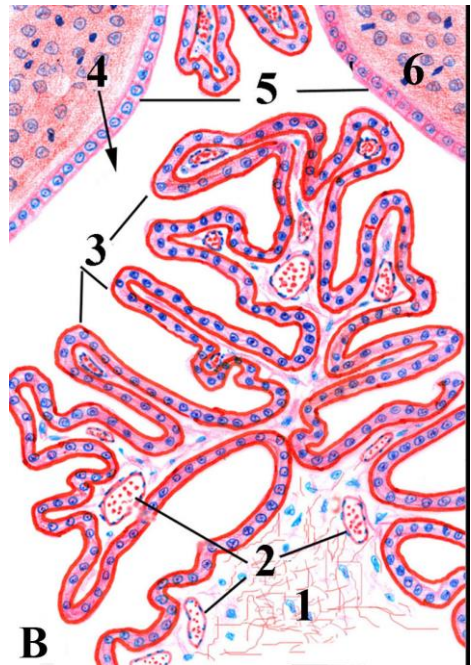


Red color indicate motor neurons and fibers; blue colour-sensory nerve fibers; green color – nonspecific sensory fibers that terminate in all layers of brain cortex; brown color – interneurons and their processes.

1. Molecular layer; 2. Outer granular layer; 3. Outer pyramidal layer; 4. Inner granular layer; 5. Inner pyramidal layer; 6. Polymorph cell layer; 7. cortico-cortical sensory fibers; 8. Descending projectional tract; 9. Thalamo-cortical fiber; 10. Commissural (callosal) motor tract; 11. Thalamo-cortical nonspecific fibers that terminate in all layers of brain cortex; 12. Motor tract that go to thalamus and claustrum; 13. Associative fibers that connect neighbouring columns; 14. Giant pyramidal neuron (Bets cell); 15. Martinotti cell; 16. Neuroglia-like neuron; 17. Large pyramidal neuron; 18. Basket neuron; 19. Modified pyramidal neuron; 20. Small pyramidal neuron; 21. Spiny stellate neuron; 22. Nonspiny stellate neuron; 23. Chandellier cell; 24. Inhibitory pyramidal cell; 25. Horizontal neuron.



A



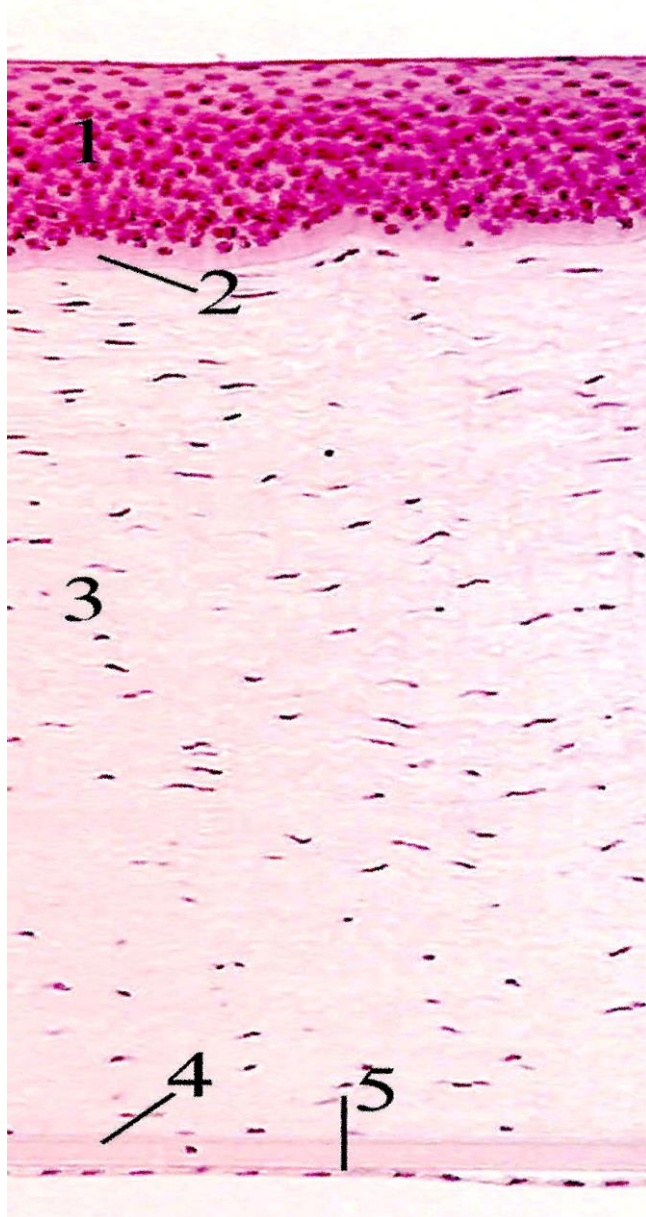
B

**A. Structures of blood-brain barrier..**

1. perivascular astrocytic feetend; 2. Outer lamina lucida of basement membrane of blood-brain barrier; 3. Middle lamina densa of basement membrane; 4. Tight junction between endothelial cells; 5. Peripheral part of pericyte; 6. Dense layer of basement membrane; 7. Whole basement membrane; 8. Central part of pericyte; 9. Erythrocyte.

**B. Microscopic structure of choroid plexus.**

1. connective tissue elements of choroid plexus; 2. Blood vessels of choroid plexus; 3. Epithelial lining of choroid plexus; 4. Lumen of lateral ventricle; 5. Ependimocytes; 6. Region of location of neural stem cells.

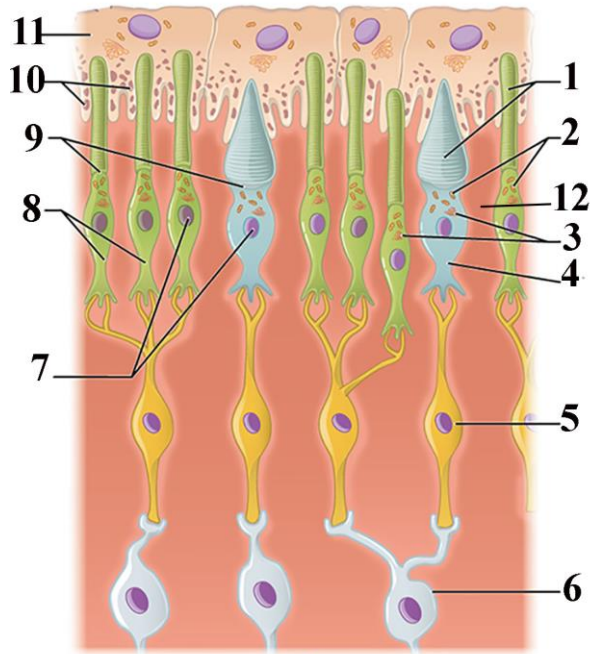


Şəkil 5.1. Рисунок 5.1.  
Microscopic structure of cornea.

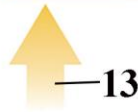
Figure 5.1.



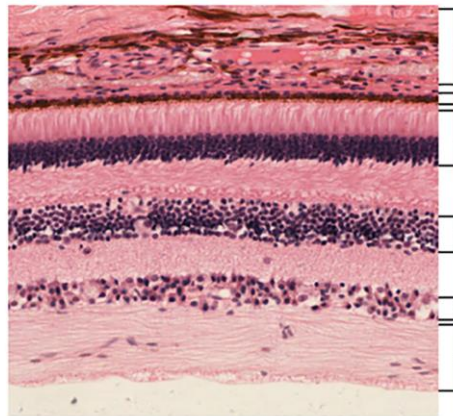
1. Corneal epithelium
2. Bowman membrane
3. Stroma of cornea
4. Dessement membrane
5. Endothelium



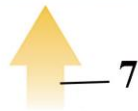
**B**



—13



**A**




—7

**Şəkil 5.2.**      **Рисунок 5.2.**      **Figure 5.2.**  
**A) Histological structure of retina**  
 1. Vascular tunic  
 2. Pigmented epithelium

3. Rods and cones
4. Bipolar cells
5. Ganglionar cells
6. Optic nerve
7. Direction of light

**B) Schematic illustration of histological structure of retina**

1. discs of rods and cones
2. mitochondria
3. Golgi apparatus
4. cone
5. bipolar cell
6. ganglion cell
7. types of cones and rods
8. rods
9. cilium (connecting part)
10. melanin granules
11. pigment cells
12. glial cells (Muller)
13. direction of light



Şəkil 5.3.

Рисунок 5.3.

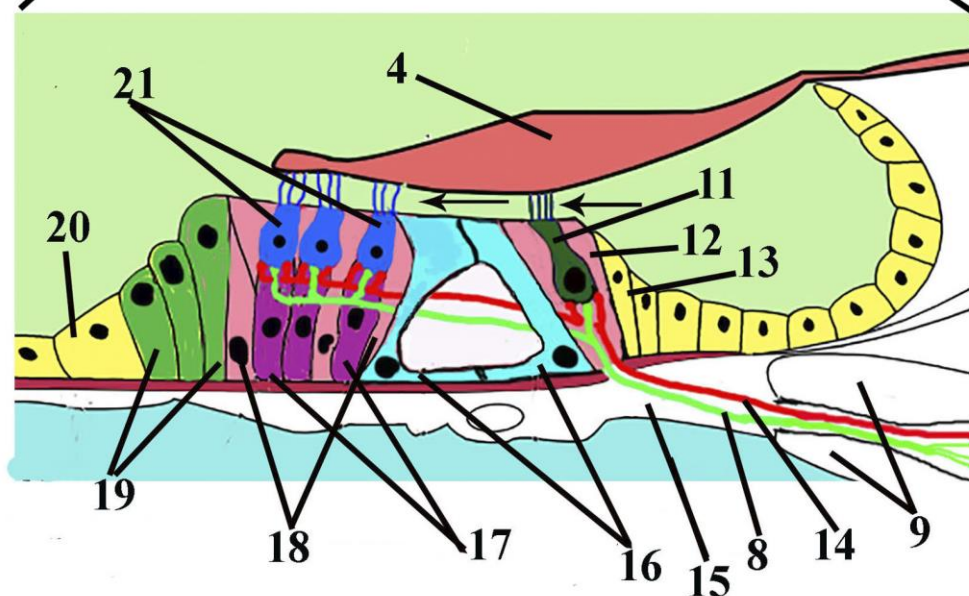
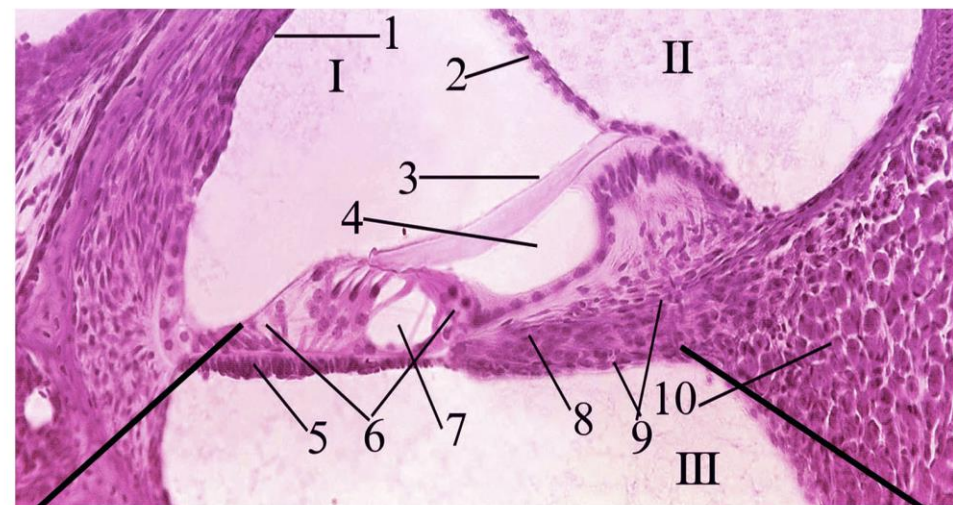
Figure 5.3.

### Ultrastructure of olfactory epithelium

1. basement membrane
2. nucleus of basal cells
3. axon of olfactory neuron
4. cytoplasm of olfactory cell
5. nucleus of olfactory cell
6. nucleus of supporting cell
7. dendrite of olfactory cell
8. intercellular tight junction
9. bulb of olfactory neuron
10. cilia of dendrite
11. supporting cells microvilli

Organ of hearing and balance.  
Organ of taste.

6

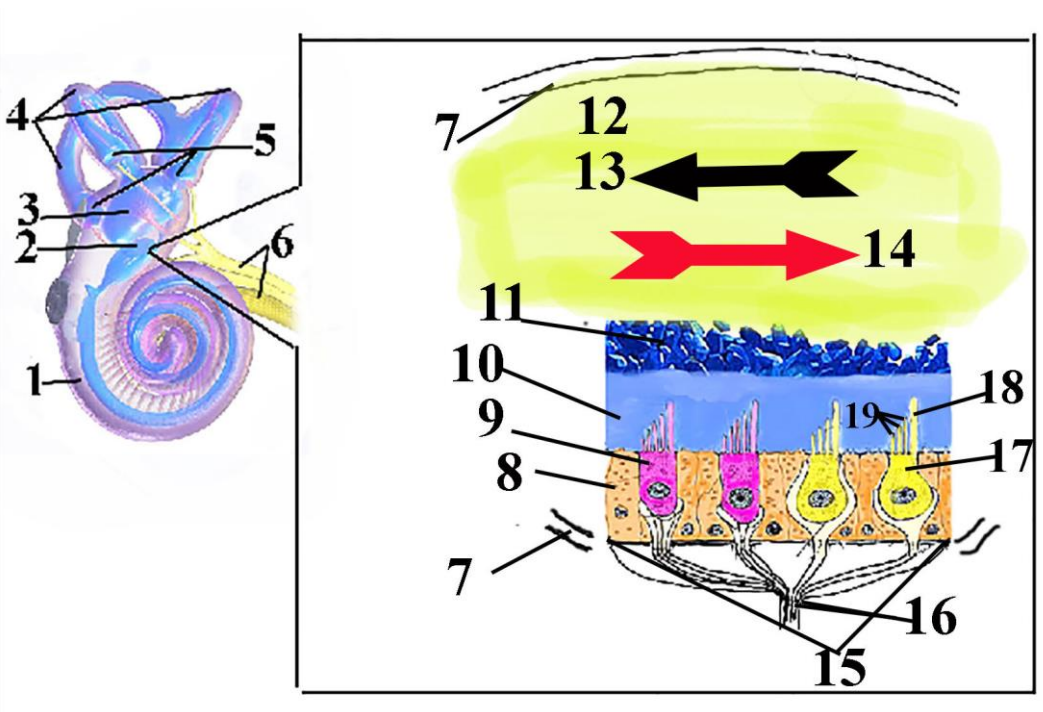


Şəkil 6.1.      Рисунок 6.1.      Figure 6.1.  
Histological structure (upper part) and schematic illustration  
(lower part) of organ of Corti.

I. Spiral duct; II. Scala vestibuli; III. Scala tympani.

1. stria vascularis; 2. Vestibular membrane; 3. Tectorial membrane; 4. Tunnel; 5. Basilar membrane; 6. Organ of Corti; 7. Internal tunnel; 8. Dendrites of cells in spiral ganglion; 9. osseous spiral lamina; 10. spiral ganglion.

**Parts of scheme.** 4. Tectorial membrane, 11. Inner hair cells, 12. Inner falangeal cell, 13. Internal border cell, 14. Motor nerve fibers, 15. basal membrane, 16. Outer and inner pillar cells, 17. Cells of Deuters that are in contact with outer hair cells, 18. Outer falangeal cells, 19. Outer border cells (Hensen cells), 20. Outer cuboidal supporting cells (Claudius). 21. Outer hair cells



Şəkil 6.2.

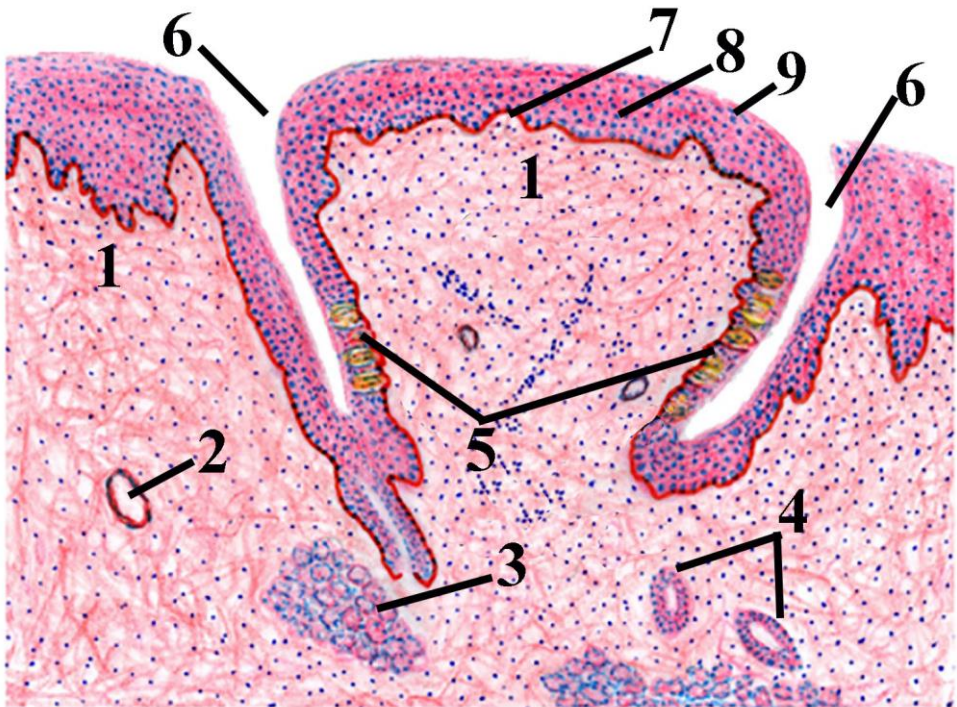
Рисунок 6.2.

Figure 6.2.



**Schematic structure of inner ear (on the left) and macula of saccule (on the right).**

1. Cochlea, 2. Saccule, 3. Utricule, 4. Semicircular canals, 5. Cristae of semicircular canals, 6. Vestibulocochlear nerve, 7. The wall of saccule, 8. Supporting cell of macula, 9. II type hairy cell, 10. Otholitic membrane, 11. Otholits, 12. Endolymph, 13. Direction of endolymph (inhibition of hairy cells), 14. Direction of endolymph (excitation of hairy cells), 15. Macula, 16. Vestibular nerve, 17. I type hairy cell, 18. Kinocilium, 19. Stereocilium.

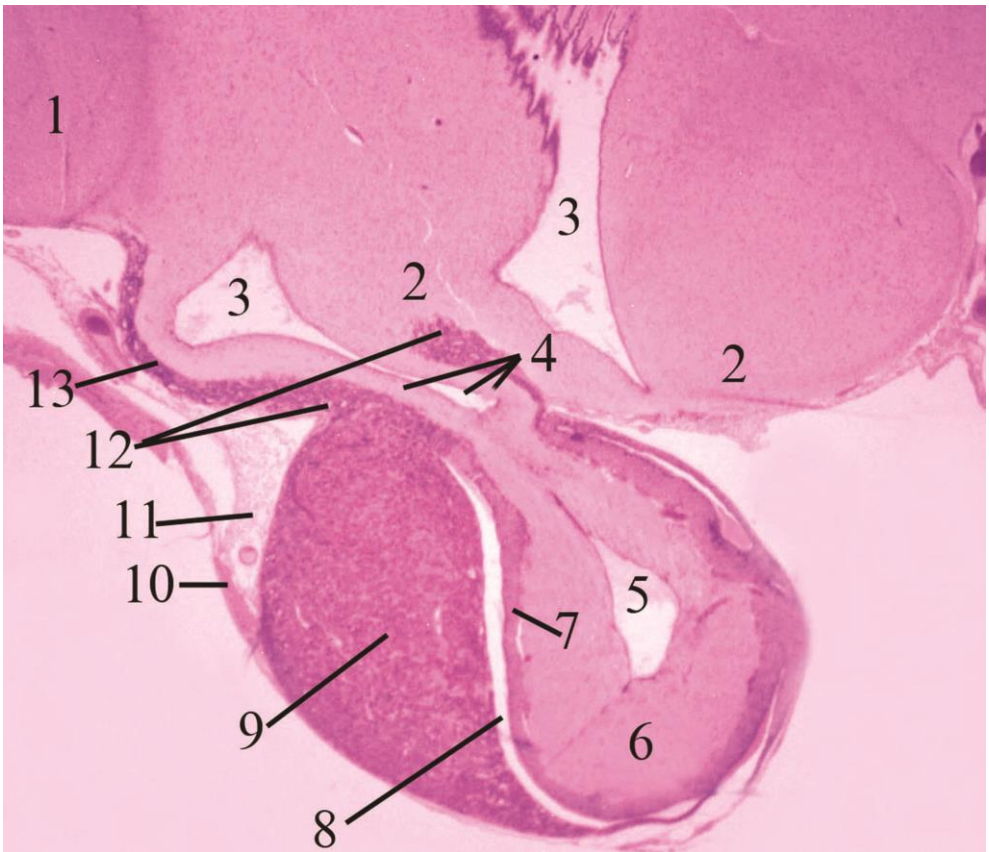


**Figure 6.3.**

**Histological structure of circumvallate papillae of tongue.**

1. Elements of dense connective tissue,
2. Blood vessels,
3. Glands of von Ebner,
4. Ducts of von Ebner glands,
5. Taste buds,
6. Fissura of papillae,
7. Basal layer of epithelium of papillae,
8. Intermediate layer of papillar epithelium,
9. Superficial layer of papillar epithelium.

<b>Hypothalamus. Pituitary gland. Pineal gland.</b>	<b>7</b>
---	----------

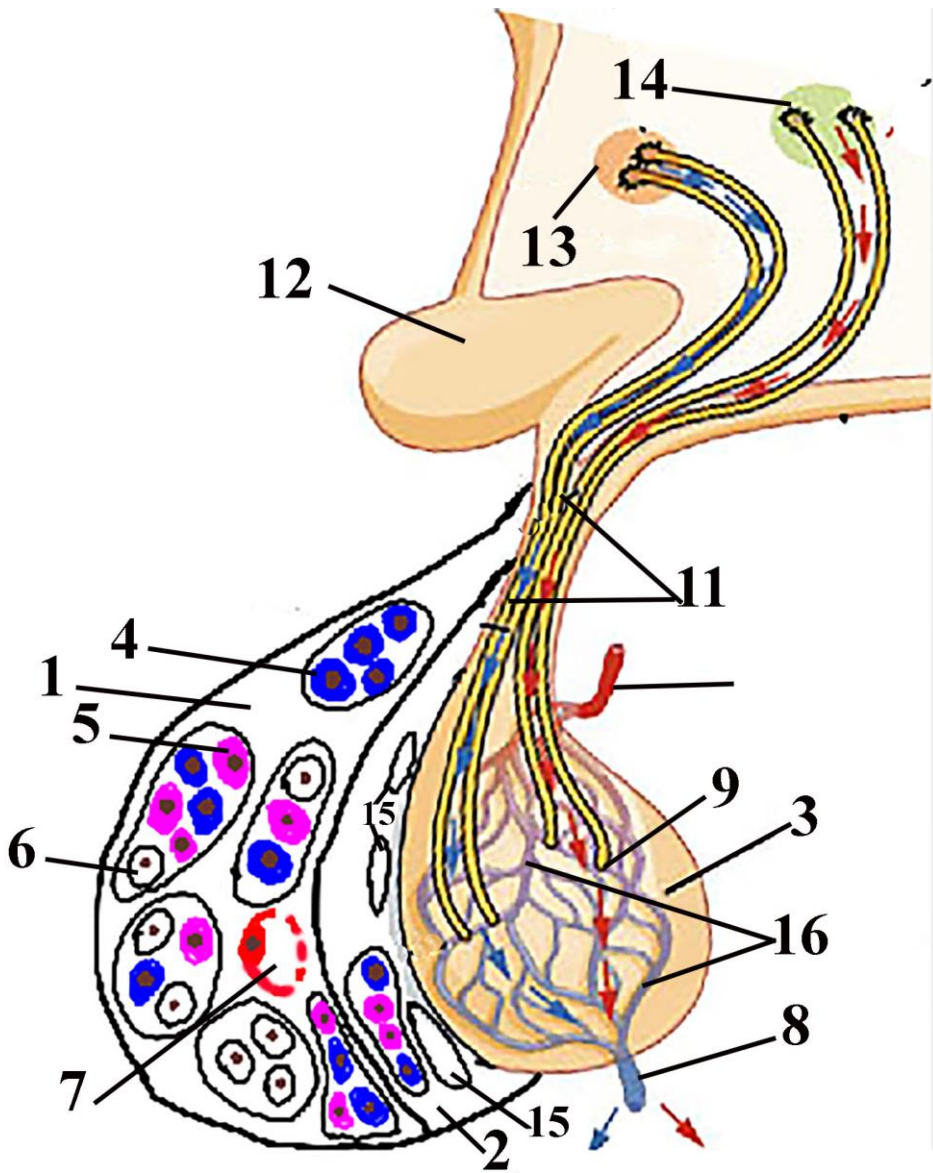


**Şakil 7.1.            Рисунок 7.1.            Figure 7.1.**  
**Histotopography of the hypothalamic structures.**



**Stain: hematoxylin and eosin.**

1. visual part of hypothalamus – optic chiasm.
2. mamillary part of hypothalamus: in left side – tuber cinereum; in right side – mamillary body
3. III ventricle pouch
4. infundibulum
5. III ventricle pouch locating into neurohypophysis
6. neurohypophysis or posterior lobe of hypophysis
7. pars intermedia
8. remnant of Ratke's pouch
9. pars distalis of hypophysis (anterior lobe of hypophysis)
10. dura mater
11. subarachnoidal space
12. part of pars intermedia surrounded infundibulum
13. pars tuberalis of adenohypophysis



Şəkil 7.2.

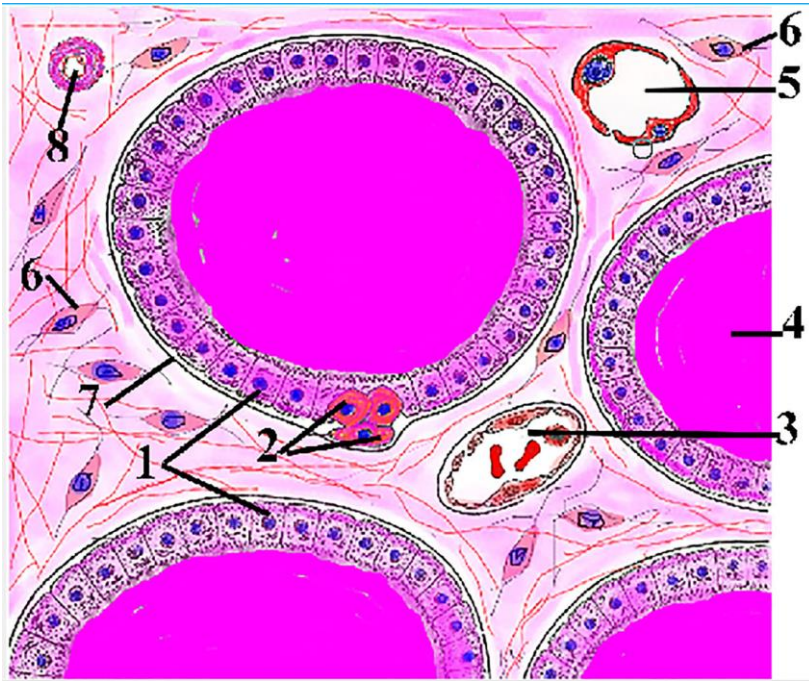
Рисунок 7.2.

Figure 7.2.

**Structures of hypothalamus and hypophysis.**

1. Adenohypophysisi,
2. Pars intermedia of hypophysis,
3. neurohypophysis,
4. Chomatophilic cell,
5. Eosinophilic cell,
6. Chromophobic cell,
7. Sinusoidal capillary,
8. Hypophysar vein,
9. Location of neurovasal synaps,
10. Inferior hypophysar artery,
11. Hypothalamohypophysar tract,
12. Chiasma opticum,
13. Superior hypophysar artery,
14. Optic chiasm,
15. Hypophysar artery,
16. Hypophysar vein.

Supraoptic nucleus, 14. Paraventricular nucleus, 15. Cyst in pars intermedia, 16. Neurohypophyseal capillary plexus.



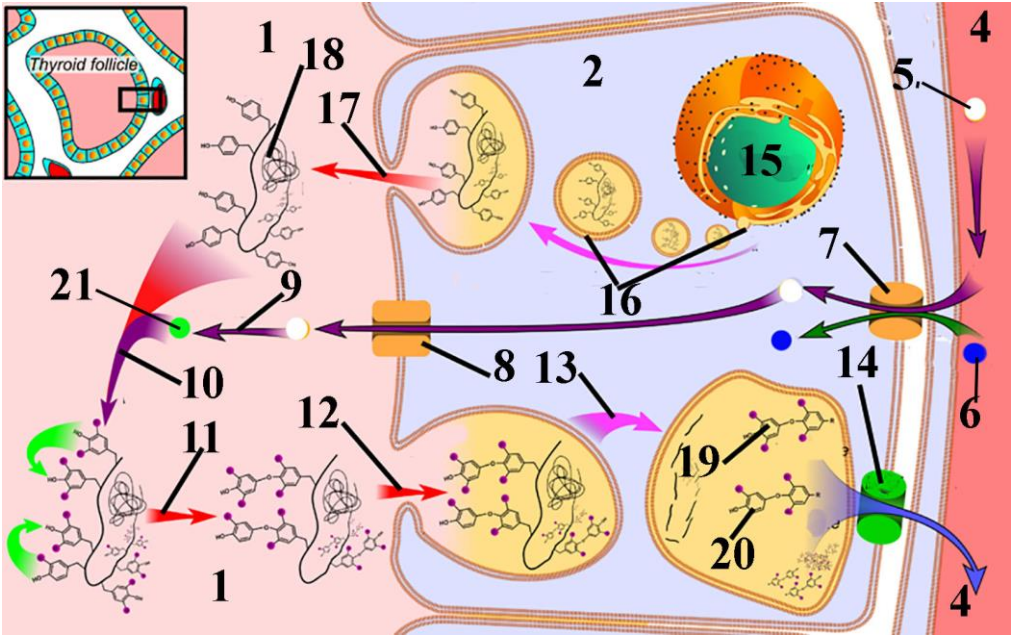
Şəkil 8.1.

Рисунок 8.1.

Figure 8.1.

**Thyroid gland. Stain: hematoxylin-eosin.**

- 1. Cuboidal T-thyrococytes; 2. C-thyrocytes (parafollicular cells),
- 3. Postcapillary venule, 4. colloid; 5. blood capillary. 6.
- Fibrocyte, 7. Basal lamina of follicule, 8. Artery.



Şəkil 8.2.

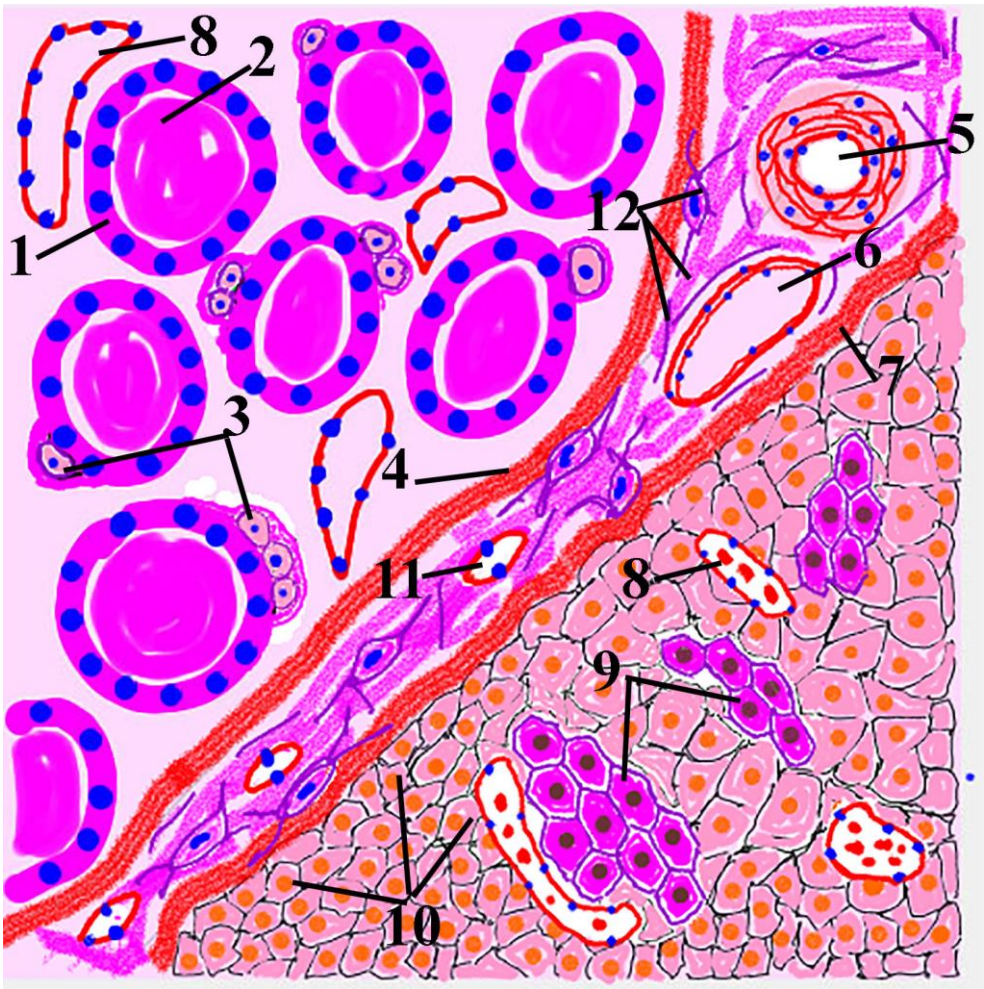
Рисунок 8.2.

Figure 8.2.

**Synthesis of thyroid hormones.**

1. Colloid, 2. T thyrocyte, 4. Blood vessel, 5. Iodide, 6. Sodium ion, 7. Sodium iodide symport carrier protein, 8. Iodide chloride symport carrier protein (pendrin), 9. Oxidation of iodide, 10. iodination, 11. Binding, 12. Endocytosis, 13. Proteolysis, 14. Carrier protein for transportation of thyroxine and triiodthyronins into the blood, 15. Nucleus, 16. Synthesis of thyroglobuline, 17. Entrance of thyroglobuline into the colloid via exocytosis, 18. Tyroglobuline, 19. Thyroxine, 20. T3, 21. Oxidised iodide.





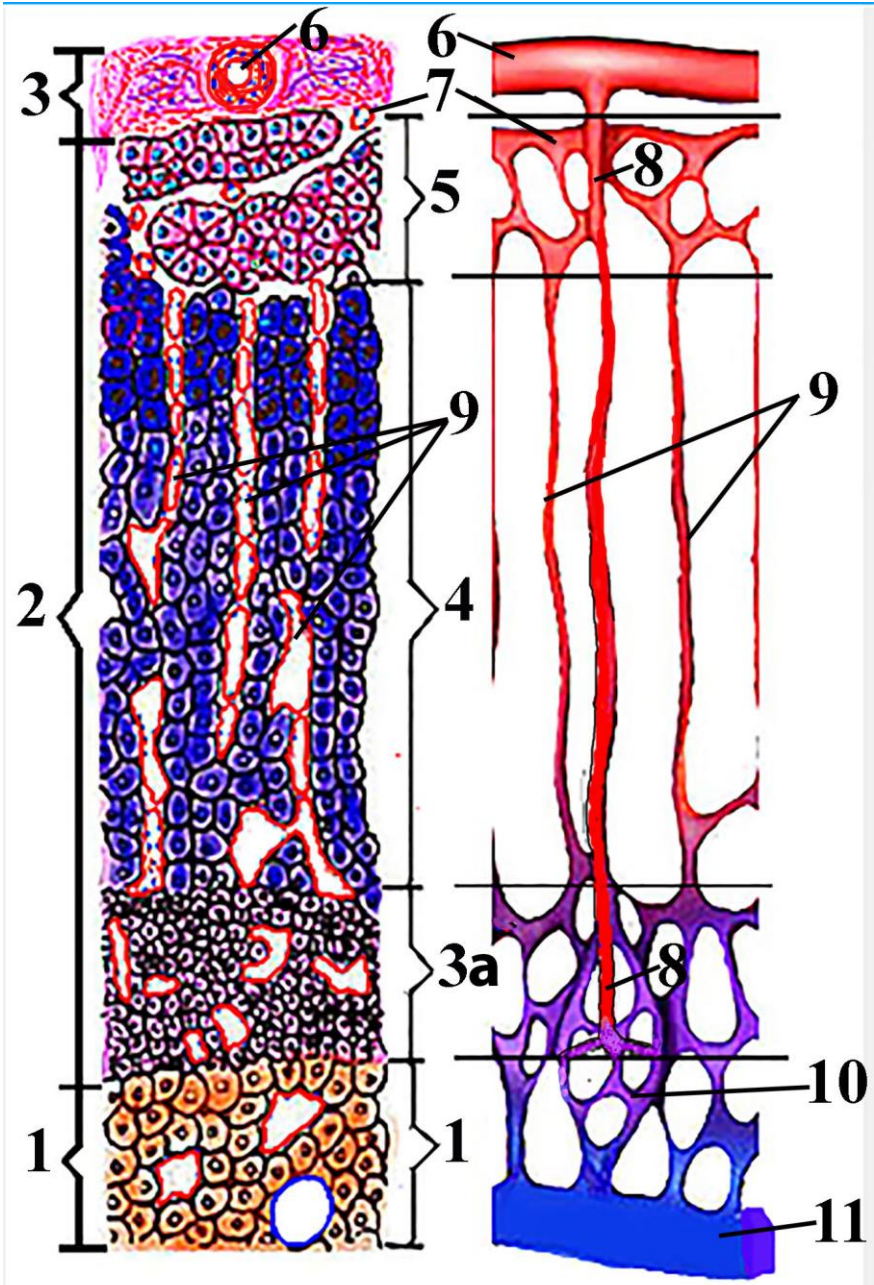
Şəkil 8.3.

Рисунок 8.3.

Figure 8.3.

**Schematic representation of thyroid and parathyroid gland.**

1. Thyrocyte, 2. Colloid; 3. Parafollicular cells (C-cells); 4. Capsule of thyroid gland; 5. Arteries; 6. Veins; 7. Capsule of parathyroid gland; 8. Synusoidal capillaries of thyroid and parathyroid glands; 9. Oxyphilic cells of parathyroid; 10. Chief cells of parathyroid gland; 11. Capillary; 12. Connective tissue elements.



**Şəkil 9.1.**

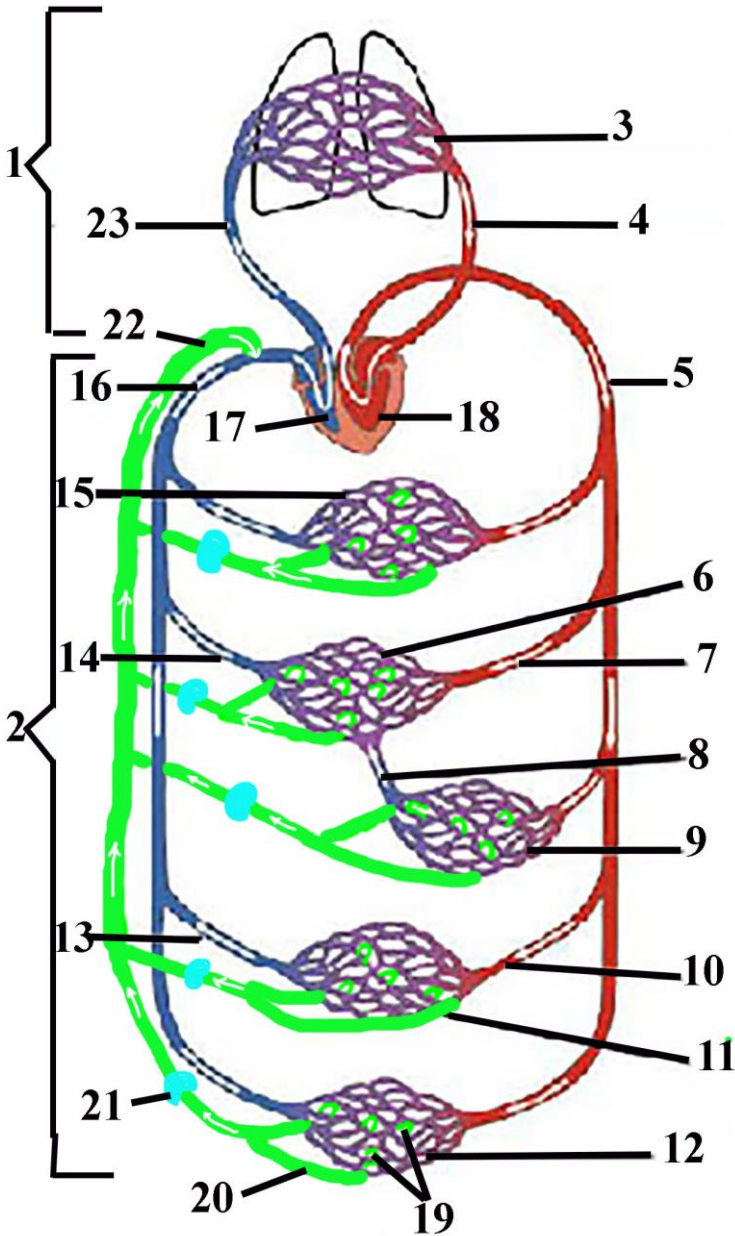
**Рисунок 9.1.**

**Figure 9.1.**

**Schematic illustrations of adrenal gland (in the left) and its blood vessels (in the right).**

1. Medulla of adrenal gland; 2. Cortex of adrenal gland; 3. Capsule of adrenal gland, 3a-zona reticularis of the cortex 4. Zona fasciculata of adrenal cortex, 5. Zona glomerulosa; 6. Capsular artery, 7. Cortical arteriole, 8. Medullary arteriole, 9. adrenokortikal sinusoidal capillary, 10. Capillary network of medulla. 11. Adrenal vein.






Şəkil 10.1. Рисунок 10.1. Figure 10.1.  
Schematic representation of the blood circulation.

10.1.

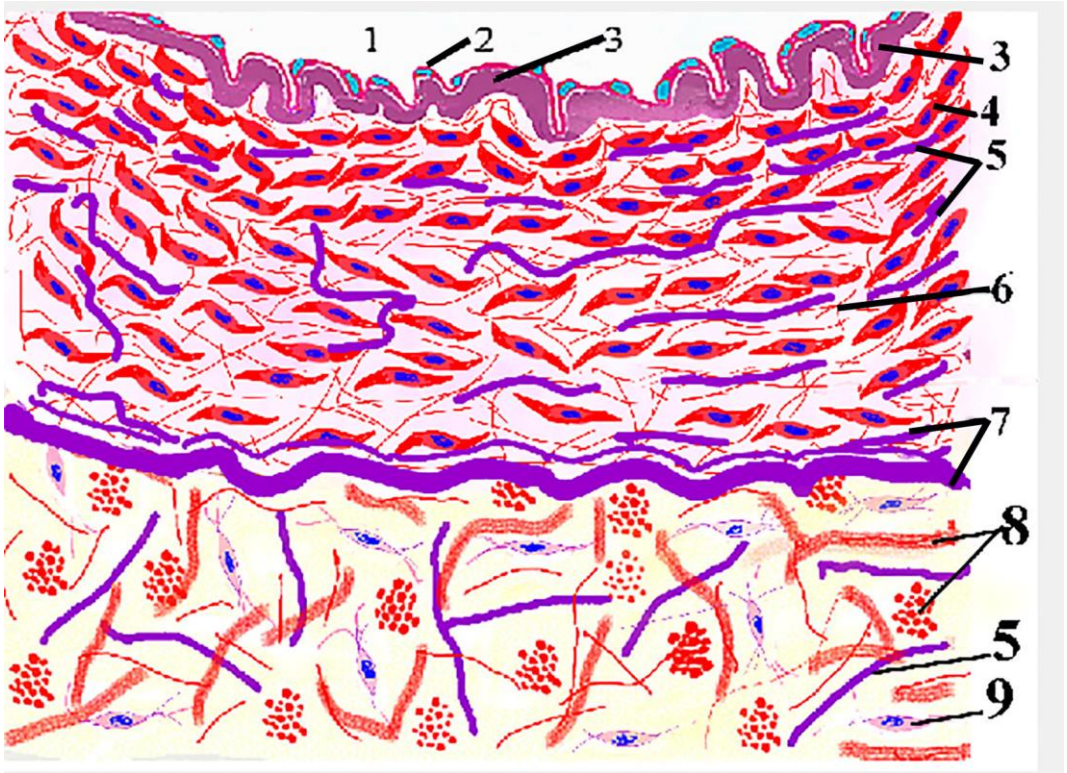
1. Pulmonary circuit. 2. S systemic circuit. 3. Lung. 4. Pulmonary veins 5. Aorta., 6. Capillary network of the liver 7. Hepatic arteries 8. Portal vein. 9. Capillary network of abdominal organs (stomach, intestine spleen), 10. renal artery. 11. Intrarenal capillary network, 12. Blood vessels of lower part of the body. 13. Renal vein. 14. Hepatic vein. 15. Blood vessel of upper part of the body, 16. Vena cavae, 17. Right ventricle, 18. Left ventricle, 19. Lymphatic capillary, 20. Lymphatic vessels (Arrows indicate direction of lymph movement), 21. Lymph node, 22. Lymphatic duct, 23. Pulmonary trunk.





**Şəkil 10.2.      Рисунок 10.2.      Figure 10.2.**  
**Schematic representation of microscopic structure of elastic artery**

1.Tunica intima, 2. Tunica media (composed mostly from fenestrated elastic membranes), 3.Tunica adventitia, 4. Endothelial cell, 5. Structures located in subendothelial layer, 6. Internal elastic plexus, 7. Fibrocytes, 8.smooth muscle cells, 9. Lumen of artery

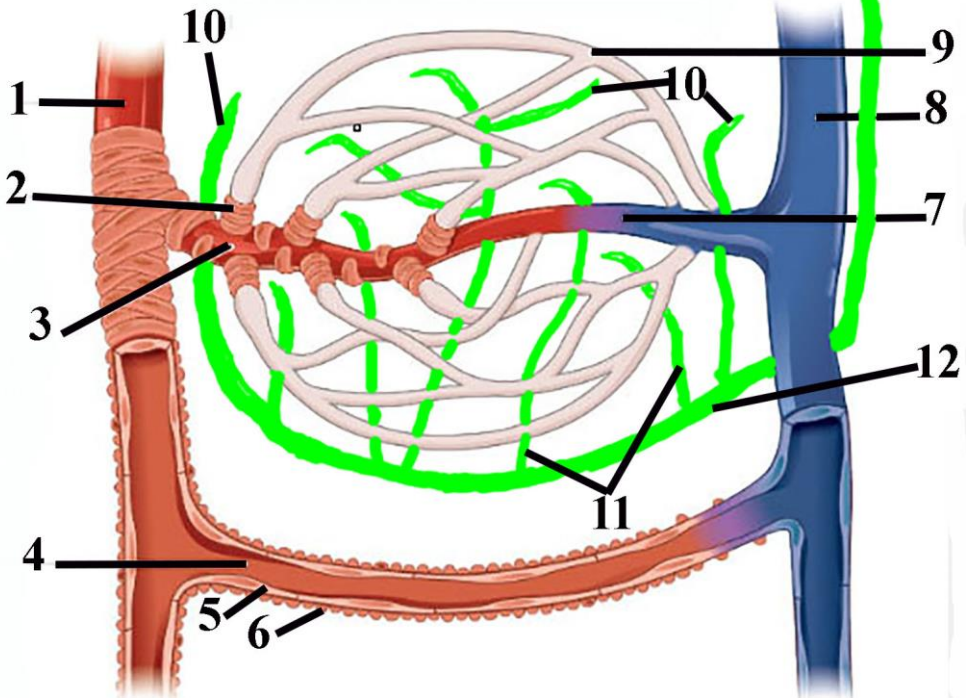


**Şəkil 10.3.            Рисунок 10.3.            Figure 10.3.**  
**Schematic representation of microscopic structure of muscular artery.**

- 1. Lumen of artery, 2. Endothelial cell of tunica intima, 3. Internal elastic lamina, 4. Smooth muscle cell, 5. Elastic fibers, 6. Bundles of collagen fibers of tunica media, 7. External elastic lamina, 8. Differently oriented bundles of collagen fibers located in adventitia, 9. Fibrocyte







Şəkil 11.1.

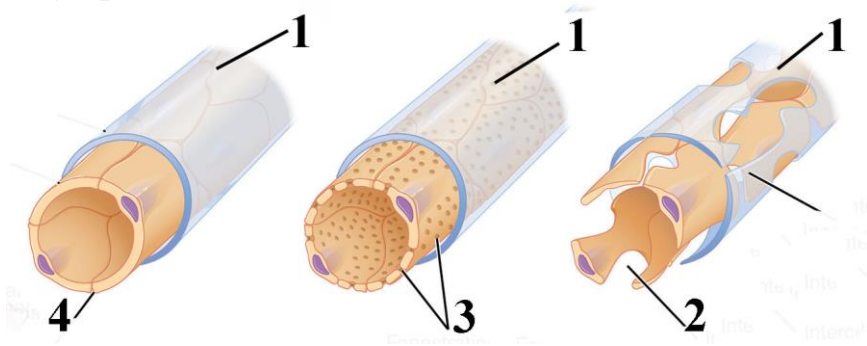
Рисунок 11.1.

Figure 11.1.

Schematic representation of microcirculatory bed.

1. Arteriole
2. Precapillary sphincter
3. Metarterioles (Act as shunt between arteriole and venule when precapillary sphincter is closed)
4. arteriovenous anastomosis
5. endothelial cells
6. smooth muscle cell
7. venous side of shunt
8. venule

- 9. blood capillary
- 10.lymphatic capillary
- 11.lympfatic postcapillary
- 12.lymphatic vessel



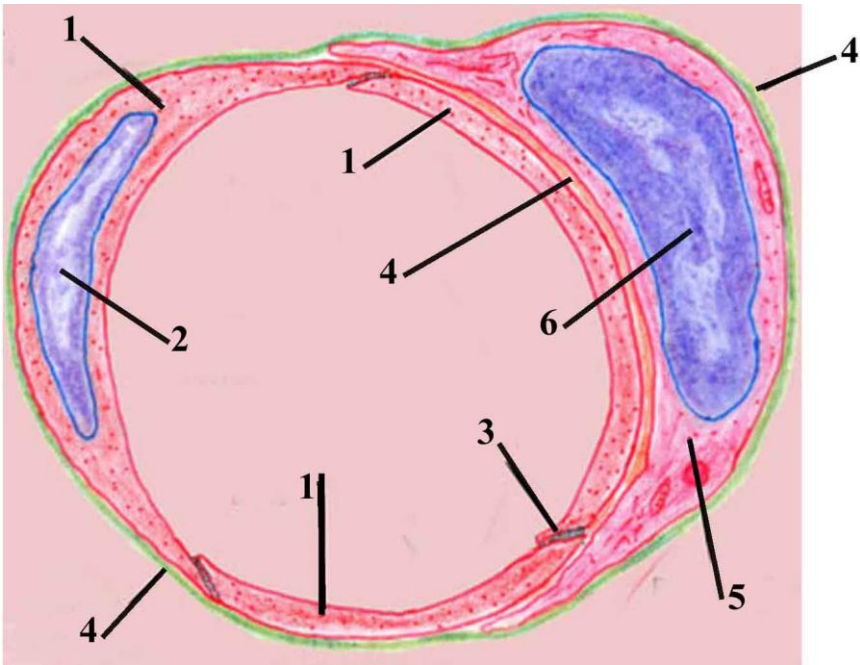
Şəkil 11.2.

Рисунок 11.2.

Figure 11.2.

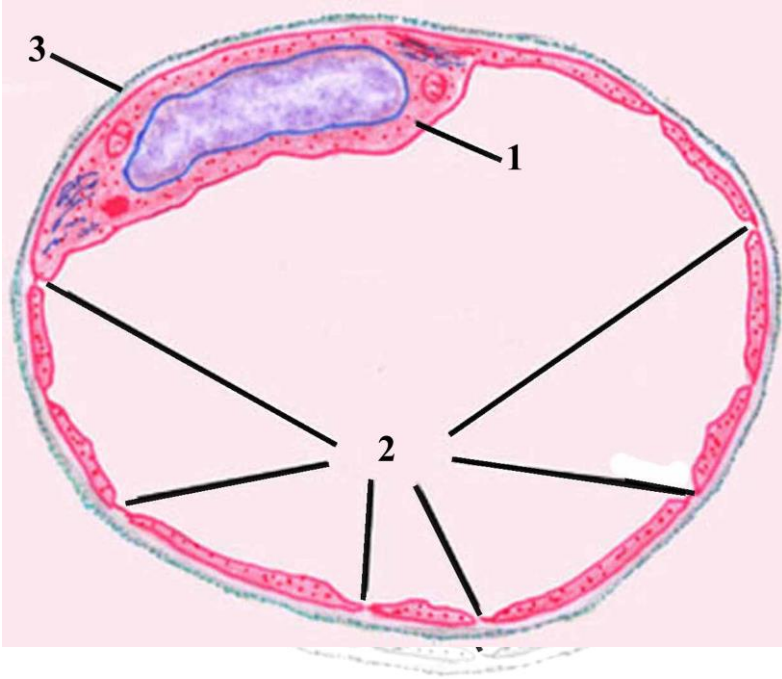
**Types of blood capillaries. Somatic type in left, visceral(fenestrated) type in the middle, sinusoidal type in right.**

- 1. Basal membrane
- 2. Intercellular cleft between endothelial cells
- 3. Fenestrae
- 4. Tight junction between endothelial cells



**Şəkil 11.3. Рисунок 11.3. Figure 11.3.**  
**Schematic representation of ultrastructural features of somatic(continuous) capillary.**

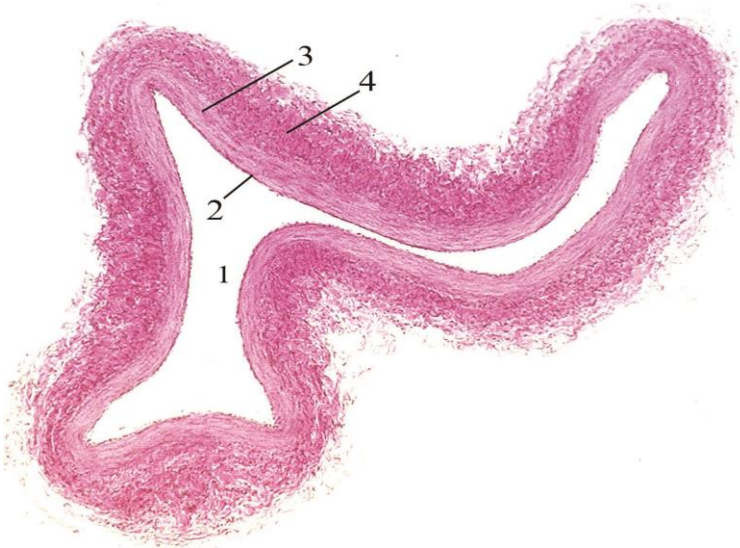
1. Cytoplasm of endothelial cell
2. Nucleus of endothelial cell
3. Intercellular junction
4. Basal lamina
5. pericyte
6. nucleus of pericyte



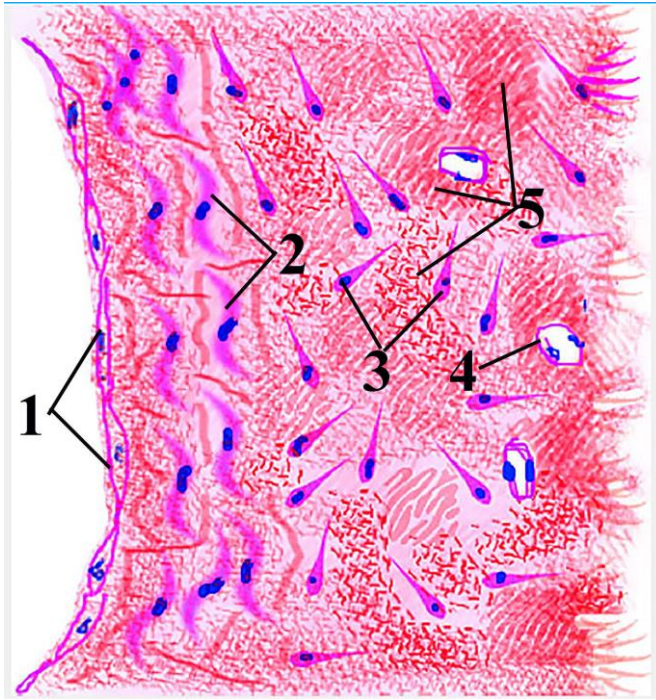
**Şəkil 11.4.      Рисунок 11.4.      Figure 11.4.**  
**Schematic representation of ultrastructural features of**  
**visceral(fenestrated) capillary**

1. endothelial cell
2. fenestrae located in peripheral regions of endothelial cells
3. basal lamina



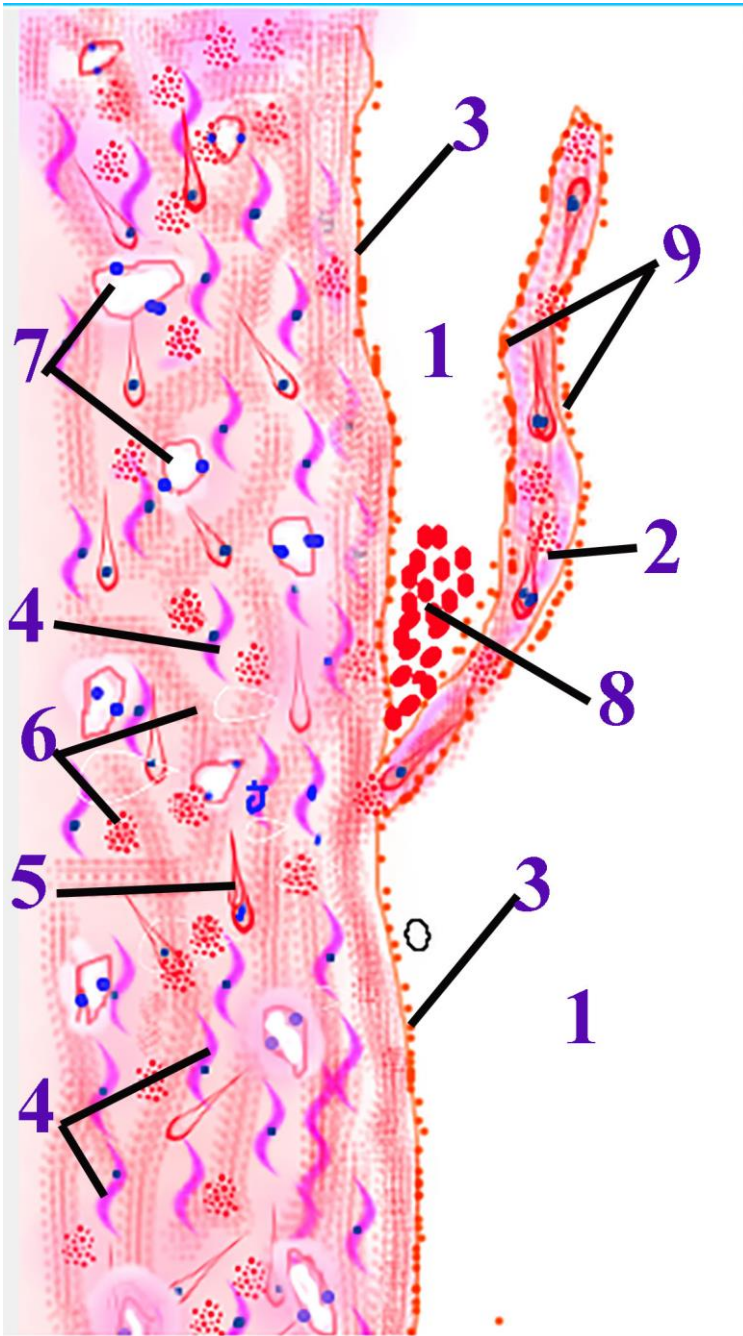


**Şəkil 12.1.      Рисунок 12.1.      Figure 12.1. .**  
**Transitional section of medium-sized vein.**  
1. lumen of vein; 2. intima; 3. media; 4. adventitia.



**Şəkil 12.2.                    Рисунок 12.2.                    Figure                    12.2.**  
**Schematic representation of histological structure medium-sized vein.**

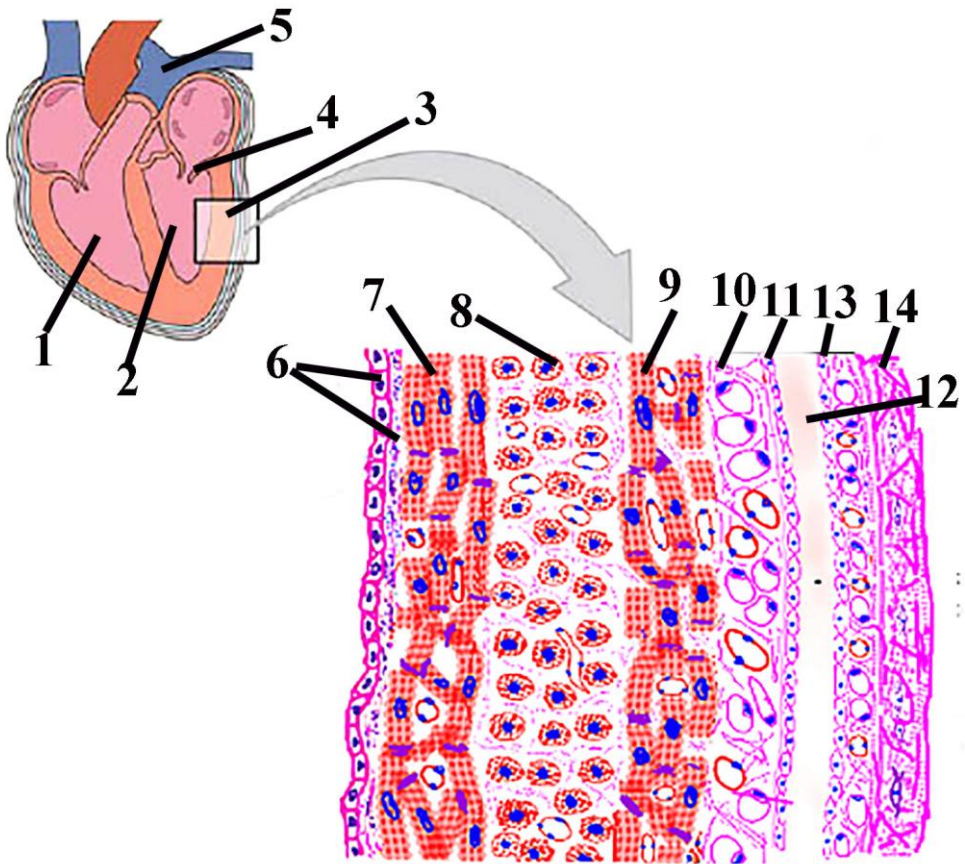
1. Endothelial cells
2. Smooth muscle cells,
3. fibrocyte
4. blood vessel,
5. differently oriented bundles of collagen fibers,



Şəkil 12.3.                      Рисунок 12.3.                      Figure 12.3.  
 Schematic representation of structures of veins with valves .

- 1. lumen of vein,
- 2. connective tissue elements that composed of valve,

3. endothelial cells.
4. Smooth muscle cell
5. fibrocyte
6. differently oriented bundles of collagen fibers,
7. blood vessels
8. formed elements of blood
9. valve



Şəkil 13.1.

Рисунок 13.1.

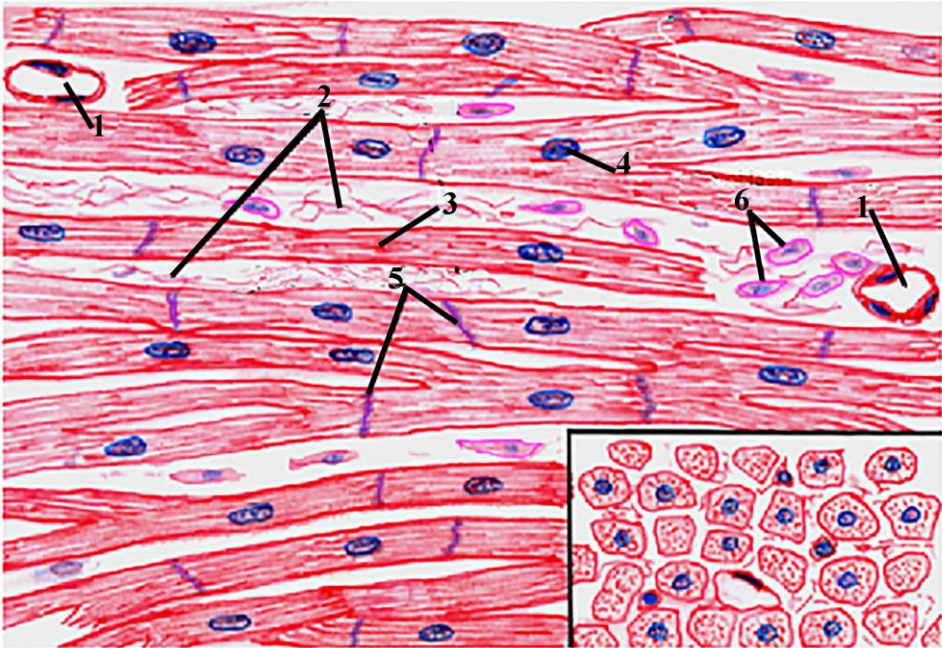
Figure 13.1.

### Schematic representation of heart wall.

1. Right ventricle
2. Left ventricle
3. Wall of left ventricle,
4. Bicuspid(mitral) valve,
5. Pulmonary trunk,
6. Endocardium,
7. Inner longitudinal layer of myocardium ,

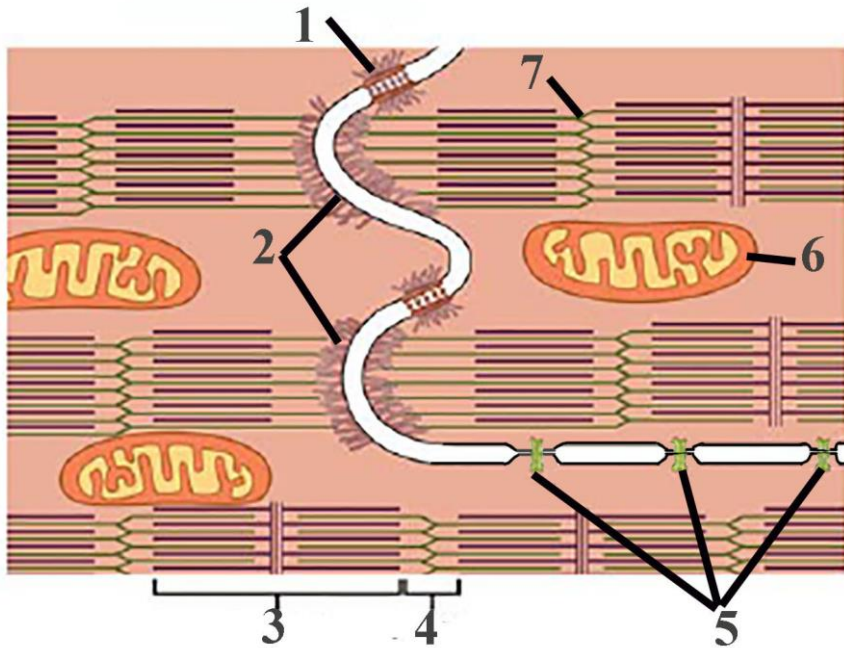


8. Transverse layer of myocardium,
9. Longitudinal layer of myocardium,
10. Connective tissue elements of epicardium,
11. Epicardial mesothelium,
12. Pericardial cavity,
13. Mesothelium of serous pericardium,
14. Fibrous pericardium



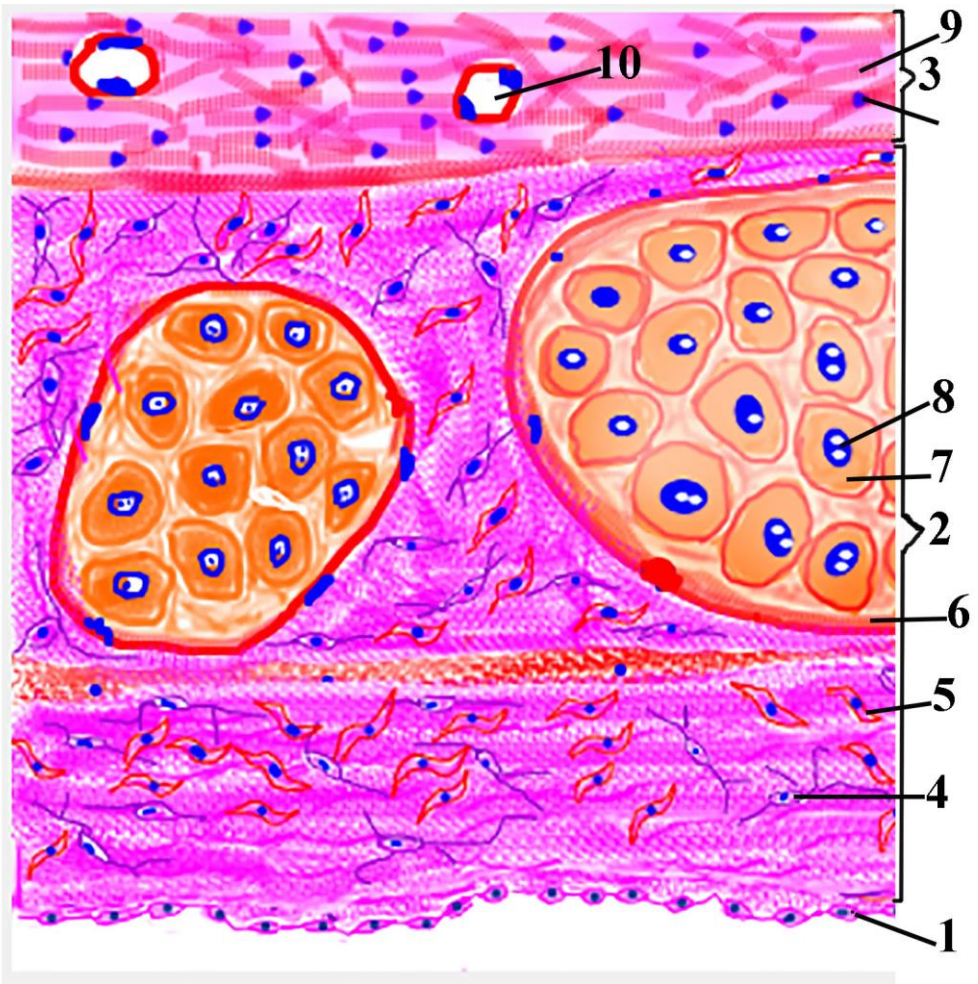
Şəkil 13.2.            Рисунок 13.2.            Figure            13.2.  
**Schematic drawing of microscopic structure of myocardium.**

1. Blood vessels
2. Fibrous structure of connective tissue,
3. Cytoplasm of cardiomyocyte,
4. Nucleus of cardiomyocyte
5. Intercalated disk,
6. fibrocyte,



**Şəkil 13.3. Рисунок 13.3. Figure 13.3.**  
**Schematic diagram of ultrastructure of intercalated disks**  
**between cardiomyocytes.**

1. Desmosome,
2. Adhering junction,
3. Anisotropic band,
4. isotropic band,
5. connexon that form gap junction
6. mitochondria,
7. Z line

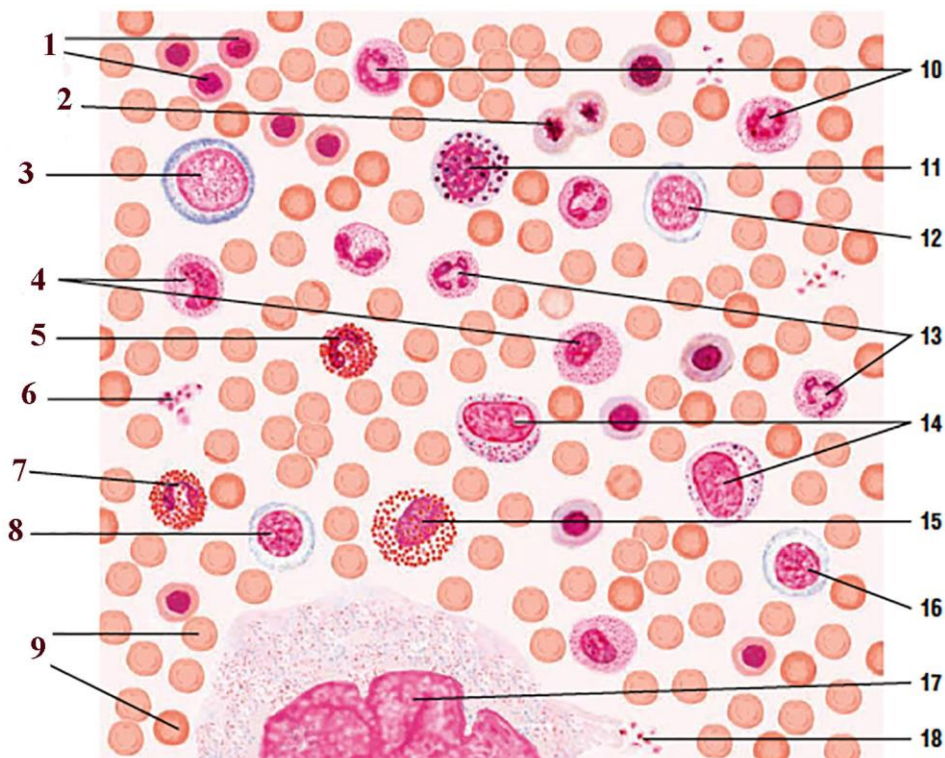


**Şəkil 13.4. Рисунок 13.4. Figure 13.4.**  
**Schematic drawing of structure of Purkinje fibers.**

1. Endothelial cell of tunica intima,
2. Endocardium
3. myocardium,
4. fibrocyte,
5. smooth muscle cell,
6. capsul of Purkinje fibers,
7. cytoplasm of atypical cardiomyocyte,
8. nucleus of atypical cardiomyocyte,

9. cardiomyocyte,
10. blood vessel



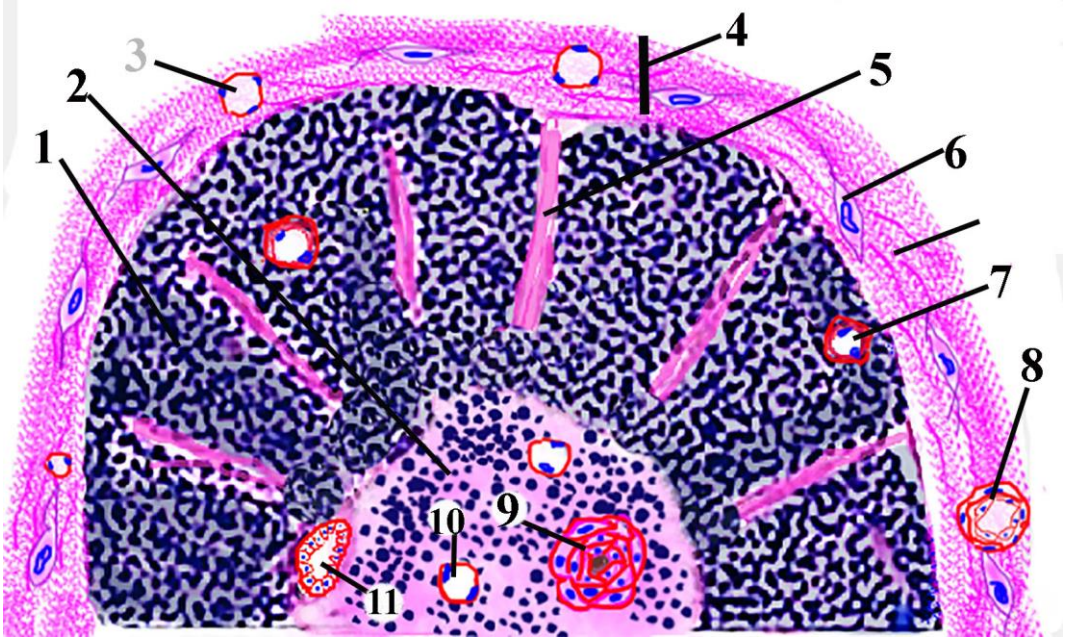


**Figure 15.1.**

**Bone marrow smear: Development of blood cells.**

- 1. Orthochromatophilic erythroblast (normoblast)**
- 2. Mitosis of orthochromatophilic erythroblast**
- 3. Proerythroblast**
- 4. Neutrophil metamyelocyte**
- 5. Eosinophilic metamyelocyte**
- 6. Trombocyte (platelets)**
- 7. Mature eosinophil**

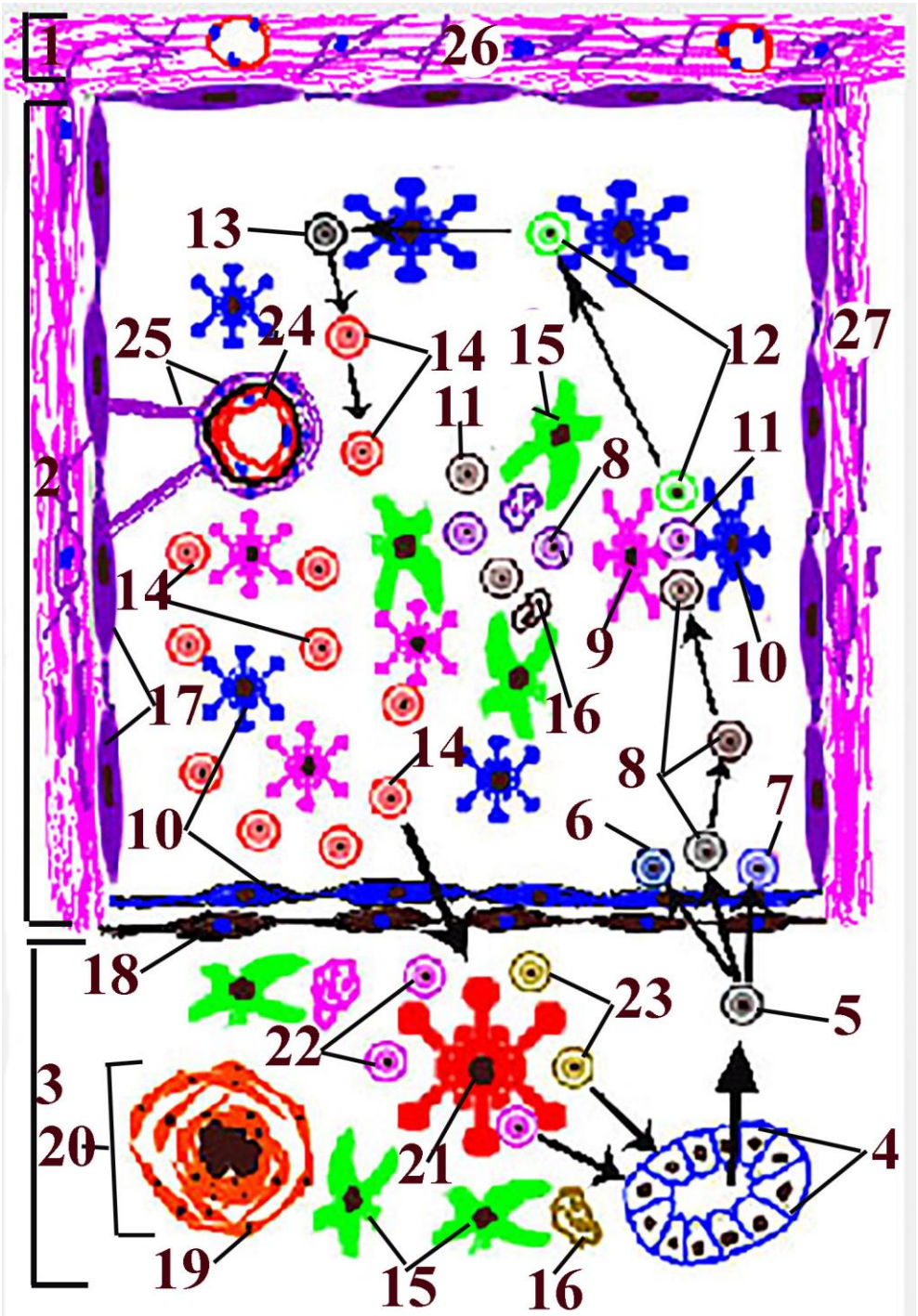
- 8. Basophilic erythroblast**
- 9. Mature erythrocytes**
- 10. Neutrophil (band cell)**
- 11. Basophilic myelocyte**
- 12. Polychromatophilic erythroblast**
- 13. Mature neutrophil**
- 14. Neutrophilic myelocyte**
- 15. Eosinophilic myelocyte**
- 16. Basophilic erythroblast**
- 17. Megakariocyte nucleus**
- 18. Trombocytes that detached from periphery of megakariocyte**



**Figure 16.1.**

**Schematic drawing of structures of thymic lobe.**

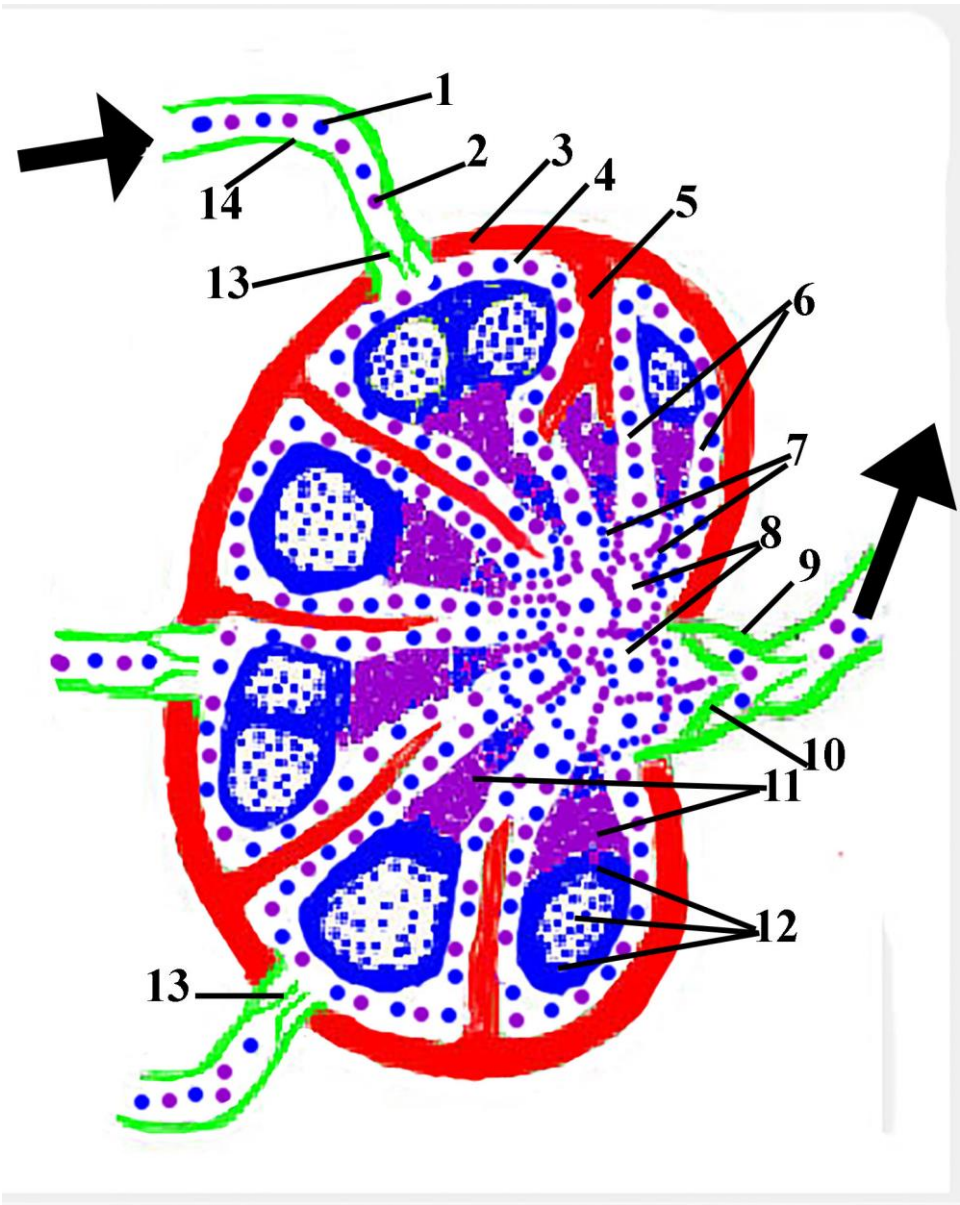
1. Cortical T-lymphocytes
2. Medulla
3. Intracapsular venule
4. Capsule of thymus
5. Interlobular septa
6. Fibrocyte
7. Capillary forming hemato-thymic barrier
8. Intracapsular arteriole
9. Thymic(Hassall's) corpuscle
10. Venule of medulla
11. High-endothelial postcapillary venule





**Şəkil 16.2.                      Рисунок 16.2.                      Figure 16.2.**  
**Schematic drawing of structures forming T-lymphocyte of thymus.**

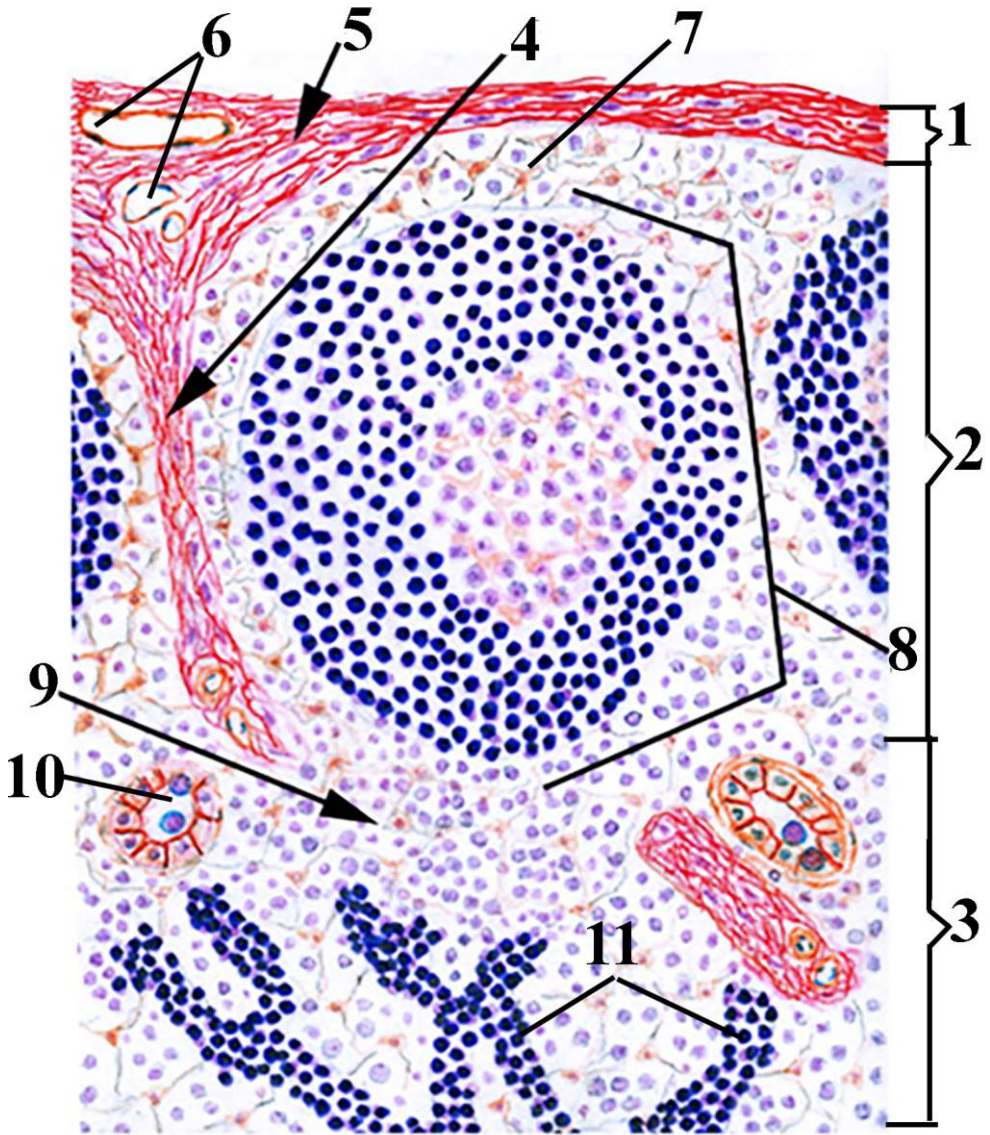
1. Capsule
2. Cortex
3. Medulla
4. High-endothelial postcapillary venule
5. Progenitor cell (CFU-L)
6. B lymphocyte
7. NK cell (natural killer cell)
8. Prothymocyte (double-negative - CD4 və CD8 negative)
9. Type II epithelial reticular cell
10. Type III epithelial reticular cell
11. Double-negative cells that intentionally killed by apoptosis
12. Developing double-negative cells
13. Pre- double positive cells
14. Double positive cells
15. Macrophage
16. Cells undergo apoptosis phagocytosed by macrophage
17. Subcapsular and perivascular type I epithelial reticular cell
18. Type IV epithelial reticular cell
19. Type VI epithelial reticular cell
20. Thymic (Hassall's) corpuscle
21. Type V epithelial reticular cell
22. Single-positive CD4<sup>+</sup> T helpers
23. Single-positive CD8<sup>+</sup> cytotoxic T lymphocytes
24. Endothelial cell
25. Perivascular processes of type I epithelial reticular cells forming hemato-thymic barrier
26. Intracapsular connective tissue components
27. Connective tissue components of interlobular septa





**Figure 17.1. Schematic drawing of structure of lymph node.**

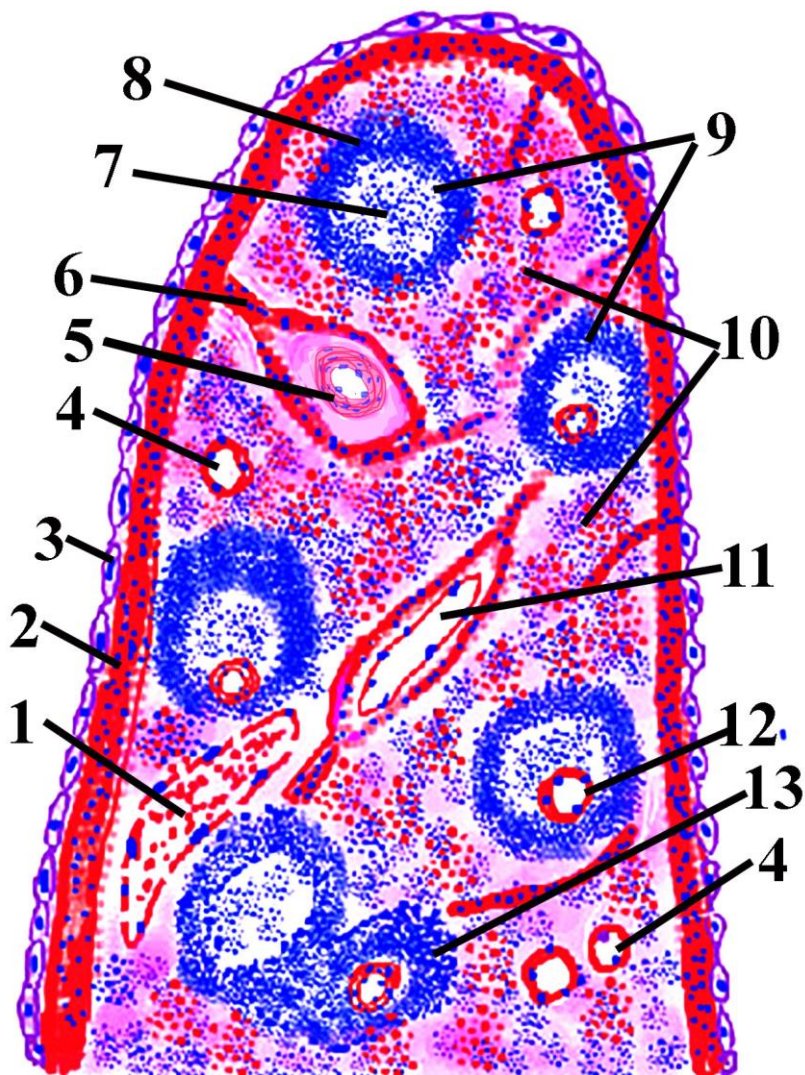
1. B-lymphocyte
2. T-lymphocyte
3. Capsule
4. Subcapsular sinus
5. Trabecula
6. Internodular cortical sinus
7. Medullary cord
8. Medullary sinus
9. Efferent lymph vessel
10. Valve of efferent lymph vessel
11. Paracortex (thymus depending zona)
12. Lymph nodule
13. Valve of afferent lymph vessel
14. Afferent lymph vessel



**Figure 17.2. Schematic drawing of histological structure of lymph node.**

- 1. capsule**
- 2. cortex**
- 3. paracortex**
- 4. trabeculae**
- 5. connective tissue elements in capsule**

- 6. blood vessels in capsule**
- 7. subcapsular sinus**
- 8. lymphoid nodule**
- 9. cortical sinus**
- 10. venula with high endothelial cells**
- 11. medullary cord**

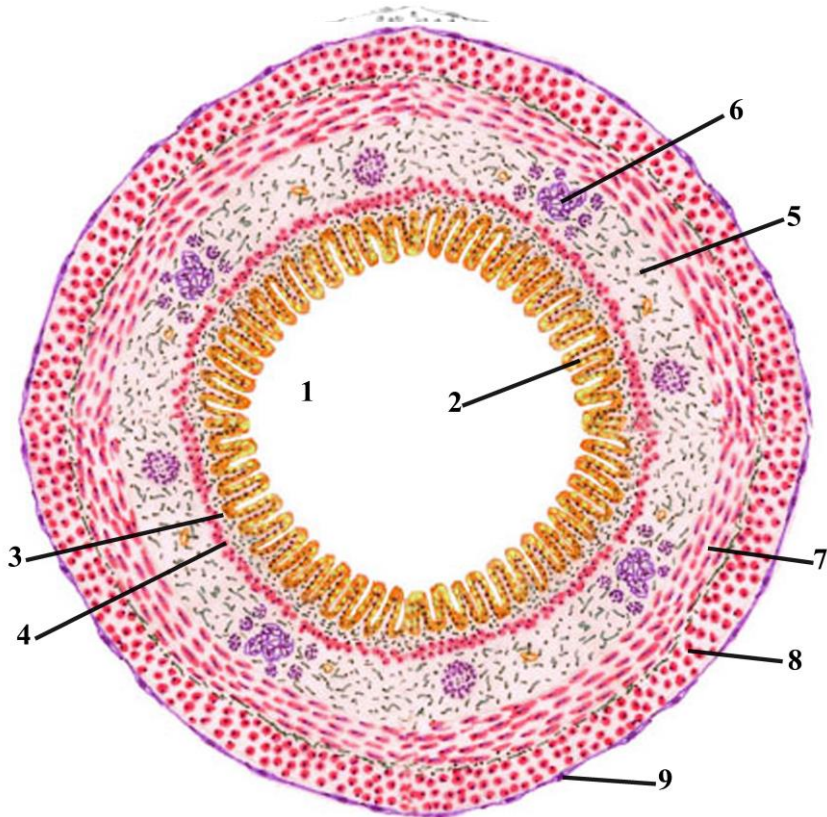


Şəkil 17.3.      Рисунок 17.3.      Figure 17.3.  
 Schematic drawing of photomicrograph of spleen.

1. Sinusoidal capillary with spindle shape endothelium of red pulp
2. Fibrous capsule of spleen
3. Mesothelium of serous layer of spleen
4. Arterial vessels of red pulp (penicillar arteriole)
5. Trabecular artery

6. Trabecula
7. Germinal center
8. Marginal zone lymphoid (Malpighian) nodule of spleen
9. Lymphatic nodules of spleen (Malpighian)
10. Red pulp
11. Trabecular vein
12. White pulp artery
13. Periarterial lymphatic sheath-PALS (T zone)



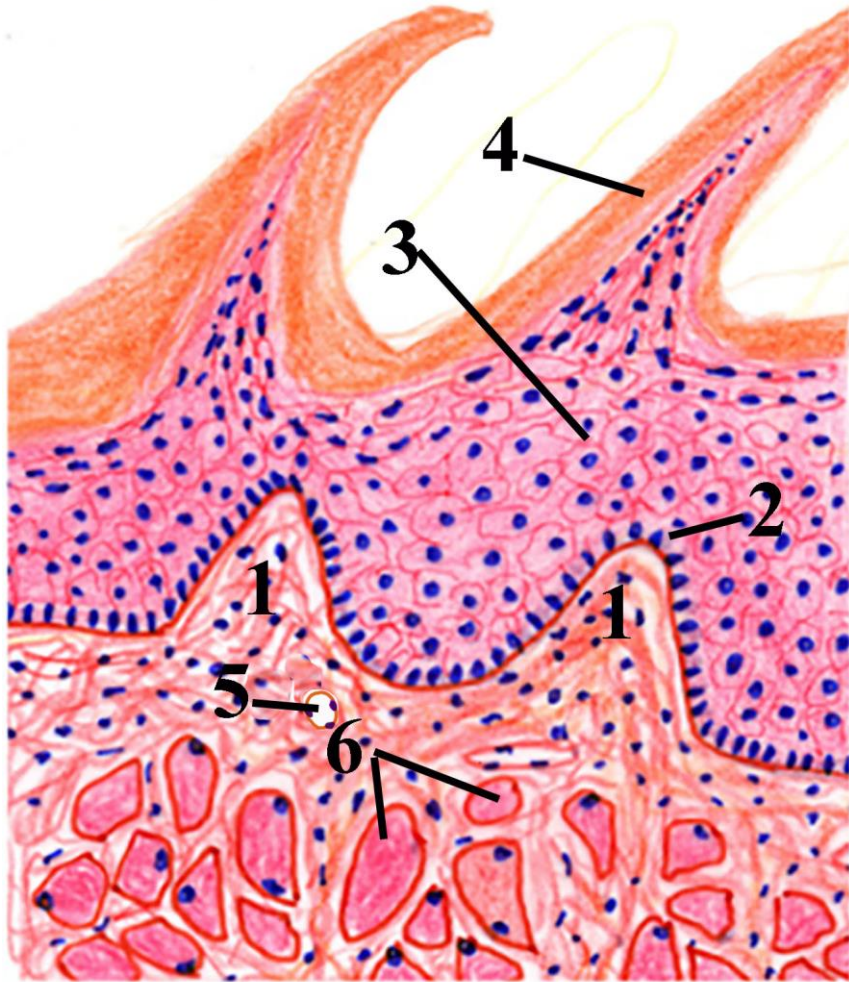


**Figure 18.1. Schematic Photomicrographs of the digestive tube organs.**

- 1. Lumen of the digestive tube**
- 2. epithelial mucosa of the digestive tube**
- 3. lamina propria**
- 4. muscularis mucosa**
- 5. submucosa**
- 6. glands in submucosa**



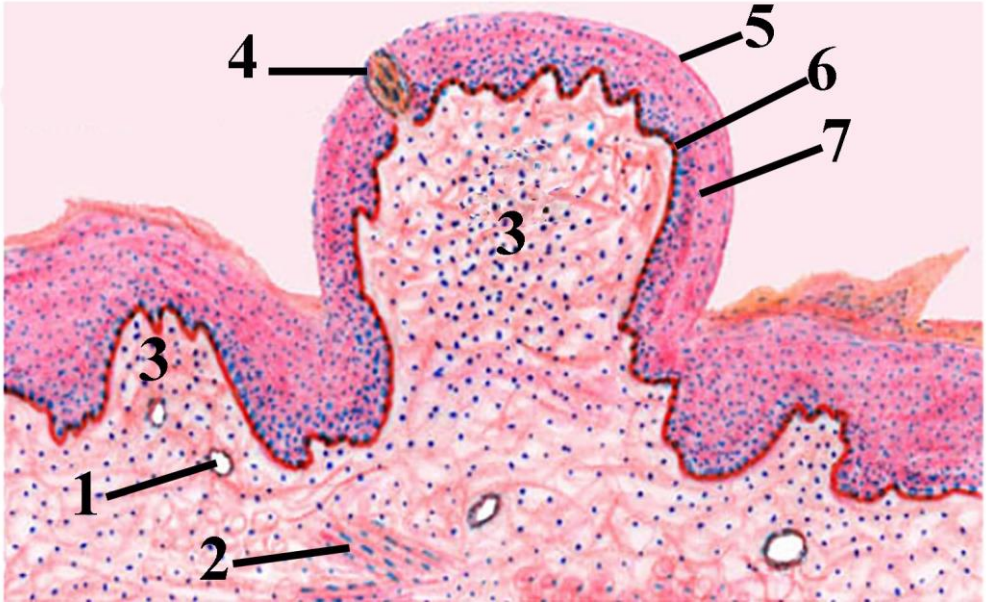
7. inner circular muscle layer
8. outer longitudinal muscle layer
9. serosa or adventitia



**Figure 18.2. Schematic drawing of structure of filiform papillae.**

1. Lamina propria of mucosa of the tongue
2. Basal layer of epithelial cover

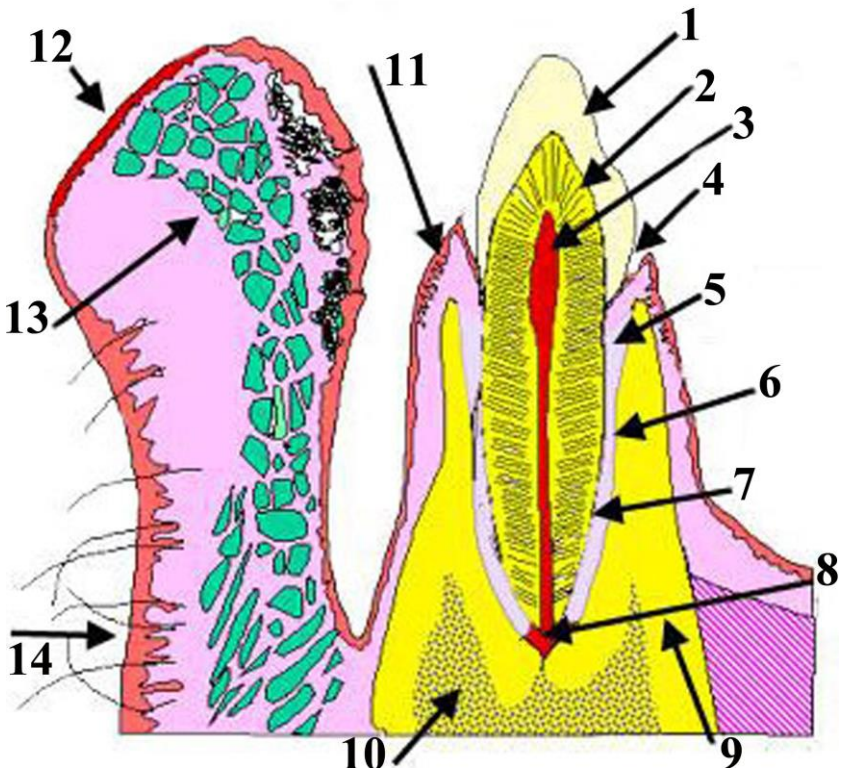
- 3. Medial layer of epithelial cover
- 4. Stratum corneum of keratinized stratified epithelium
- 5. Blood vessels
- 6. Lingual striated muscle fibers



**Figure 18.3. Schematic drawing of structure of fungiform papillae.**

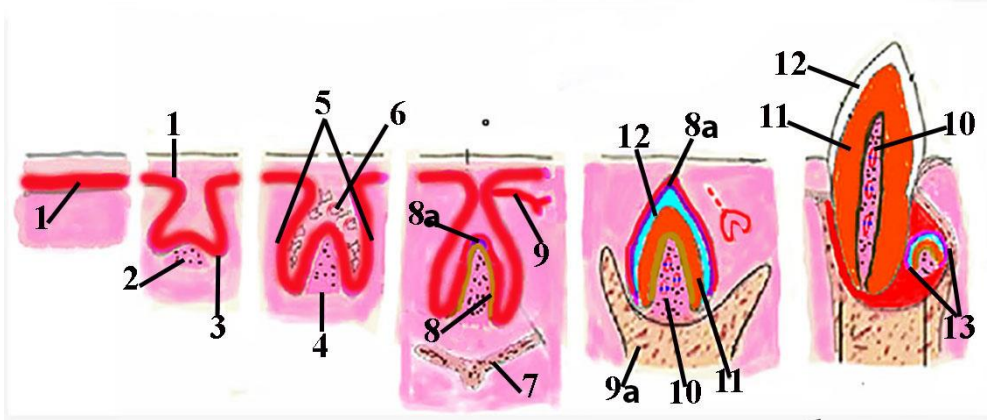
- 1. Ducts of gland
- 2. Lingual muscle
- 3. Lamina propria
- 4. Taste buds
- 5. Superficial layer of stratified squamous nonkeratinized epithelium
- 6. Medial layer of stratified squamous nonkeratinized epithelium
- 7. Basal layer of stratified squamous nonkeratinized epithelium





**Figure 19.1. Diagram of tooth and surrounding structures (alveoli and lip)**

- 1. Enamel**
- 2. dentin**
- 3. pulp**
- 4. gingival sulcus**
- 5. fibers of alveolar periosteum**
- 6. acellular cementum**
- 7. cellular cementum**
- 8. apical foramen**
- 9. compact portion of tooth alveoli**
- 10. spongy portion of tooth alveoli**
- 11.gingiva**
- 12.lip**
- 13.glands of lip**
- 14.skin covering lips**

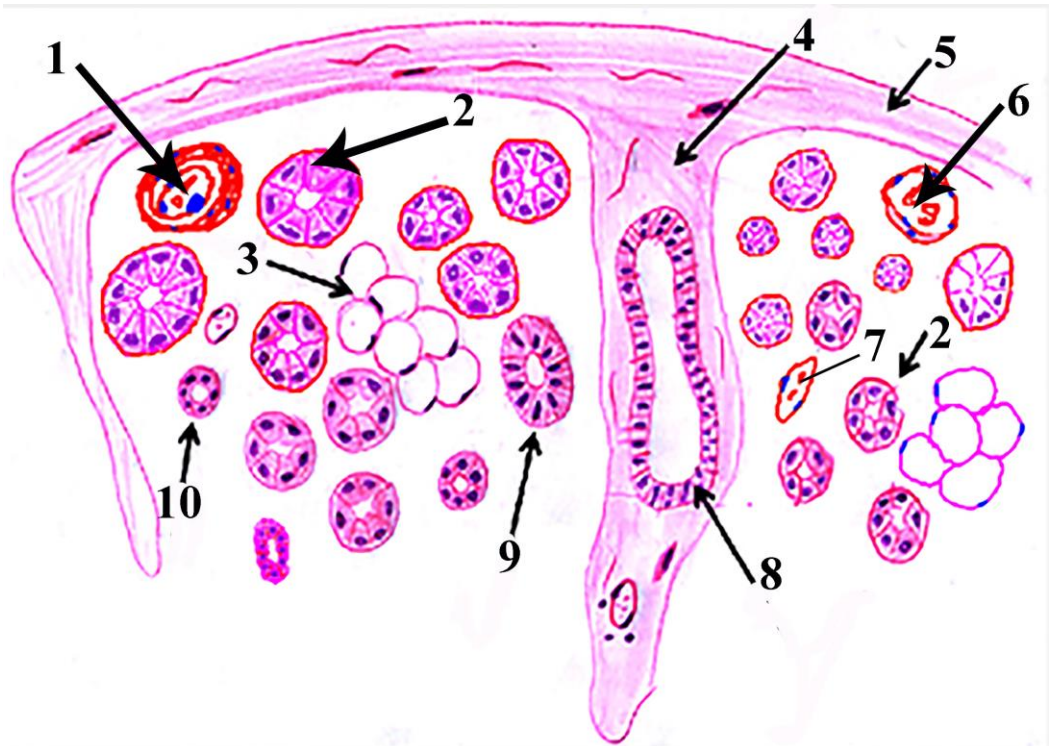


**Figure 19.2. Schematic diagram of developmental stages of deciduous teeth. From right to left : Formation of dental lamina; Bud stage; Cup stage; Bell stage; Appositional stage; Eruption of tooth.**

- 1. Dental lamina**
- 2. Condensed mesenchyme**
- 3. Enamel bud**
- 4. Dental papilla**
- 5. Enamel organ**
- 6. Pulp of enamel organ**
- 7. Germ of alveolar bone**
- 8. Dentin producing odontoblasts**
- 8a Enamel producing ameloblasts**
- 9. Germ of permanent tooth in bell stage**
- 9a Dental alveol in appositional stage**
- 10. Pulp**
- 11. Dentin**
- 12. Enamel**
- 13. Being forming germ of permanent tooth**

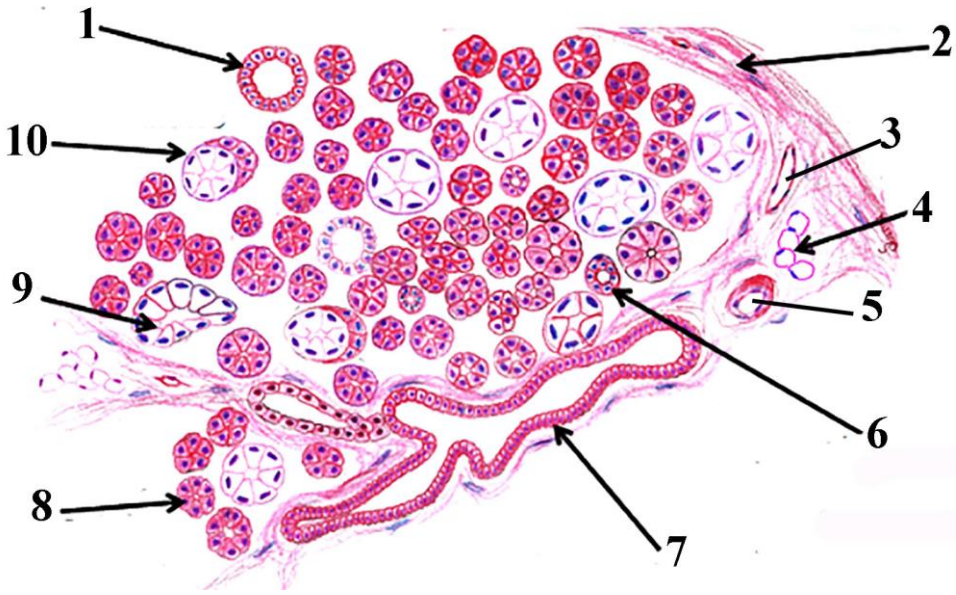






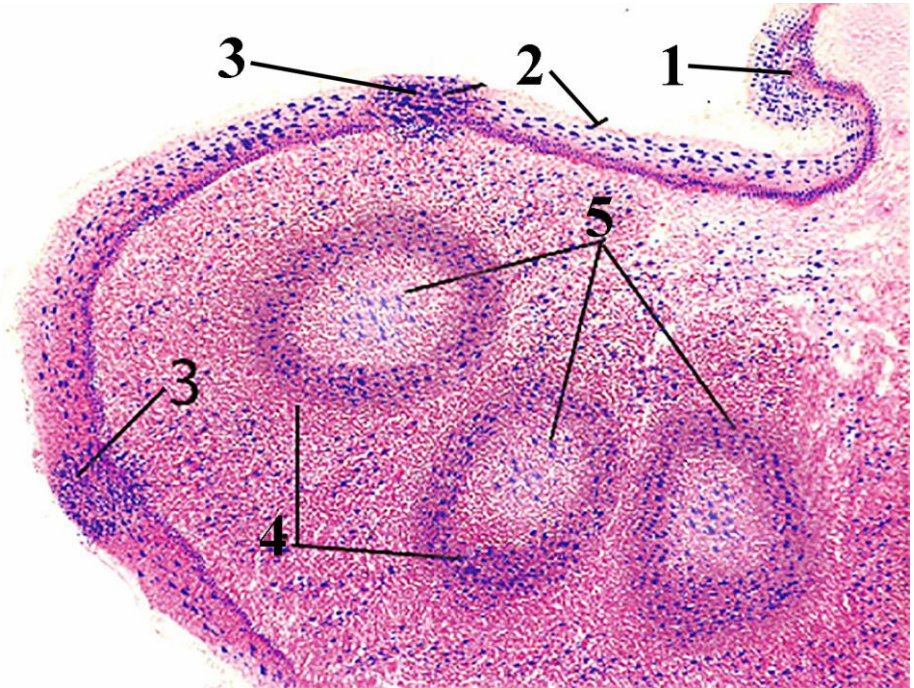
**Figure 20.1. Schematic drawing of structural elements of parotid gland .**

- 1. Artery**
- 2. Serous terminal parts**
- 3. Aggregation of adipose cells**
- 4. Interlobular septa**
- 5. Capsule**
- 6. Venule**
- 7. Capillary**
- 8. Interlobular duct**
- 9. Striated duct**
- 10. Intercalated duct**



**Figure 20.2. Schematic drawing of structural elements of submandibular (mixed) gland.**

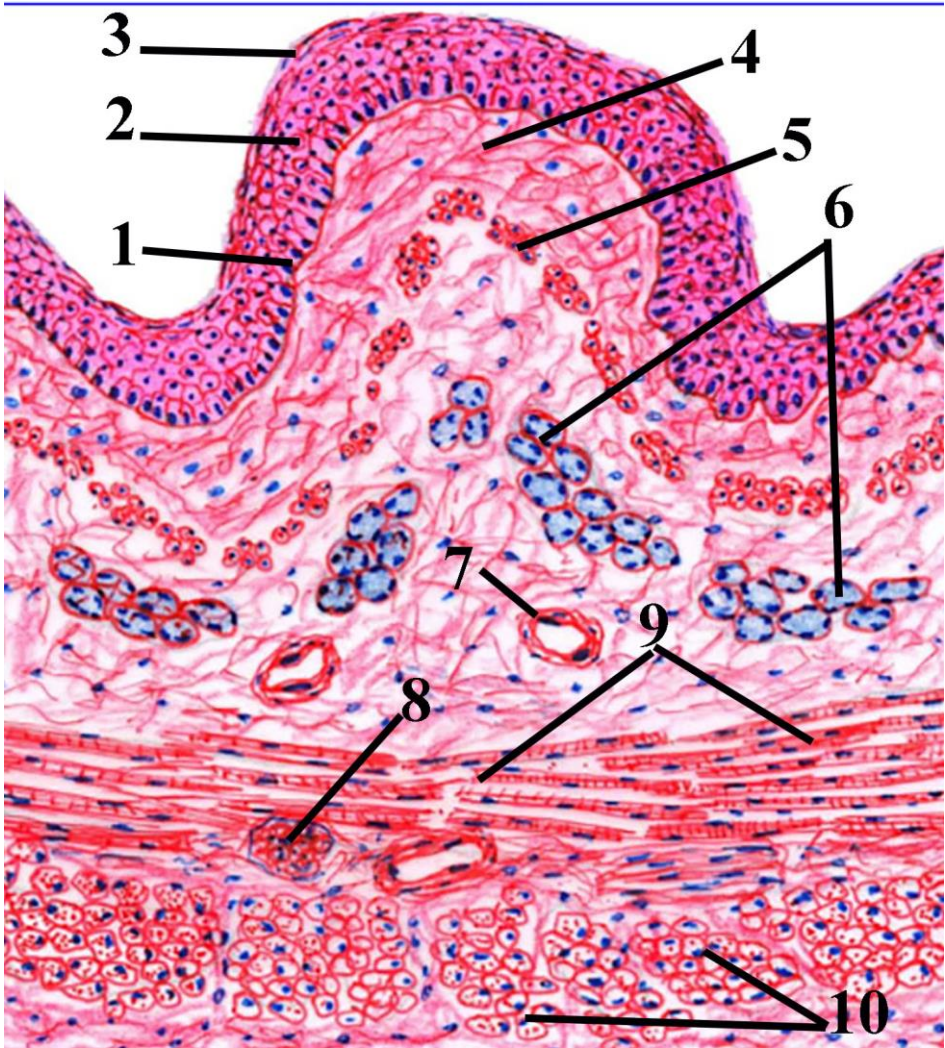
- 1. Striated duct**
- 2. Capsule**
- 3. venule**
- 4. adipocyte**
- 5. arteriole**
- 6. Intercalated duct**
- 7. intralobular duct**
- 8. Serous secretory portion**
- 9. Mucous secretory portion**
- 10. Seromucous secretory portion**



**Figure 20.3. Schematic representation of structures that participated in formation of palatine tonsils.**

- 1. Epithelium of oral cavity**
- 2. Epithelium of palatine tonsil**
- 3. Mucosa associated lymphoid tissue (MALT), part of epithelium that infiltrated with lymphocytes**
- 4. Marginal zone of lymphoid nodule**
- 5. Lymphoid nodules**



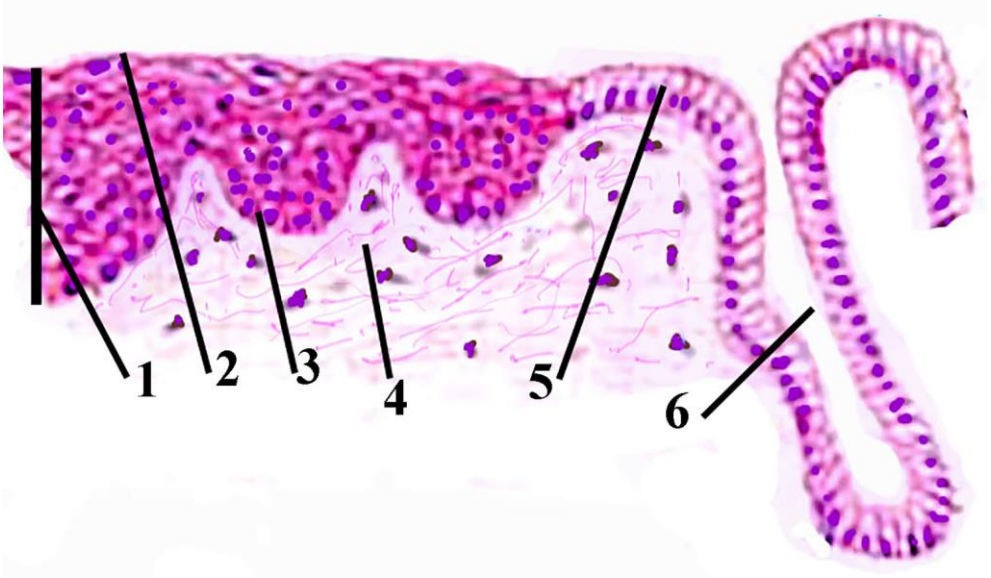


Şəkil 21.1.          Рисунок 21.1.          Figure 21.1.  
 Schematic representation of histological structure of upper  
 one third of esophagus.

1. Basal layer of nonkeratinized stratified squamous epithelium of mucosa
2. Medial epithelial layer

3. Superficial epithelial layer
4. Lamina propria of mucosa
5. Lamina muscularis of mucosa
6. Esophageal glands
7. Blood vessels
8. Autonomic ganglia
9. Internal circular striated muscle fibers layer
10. External longitudinal striated muscle fibers layer

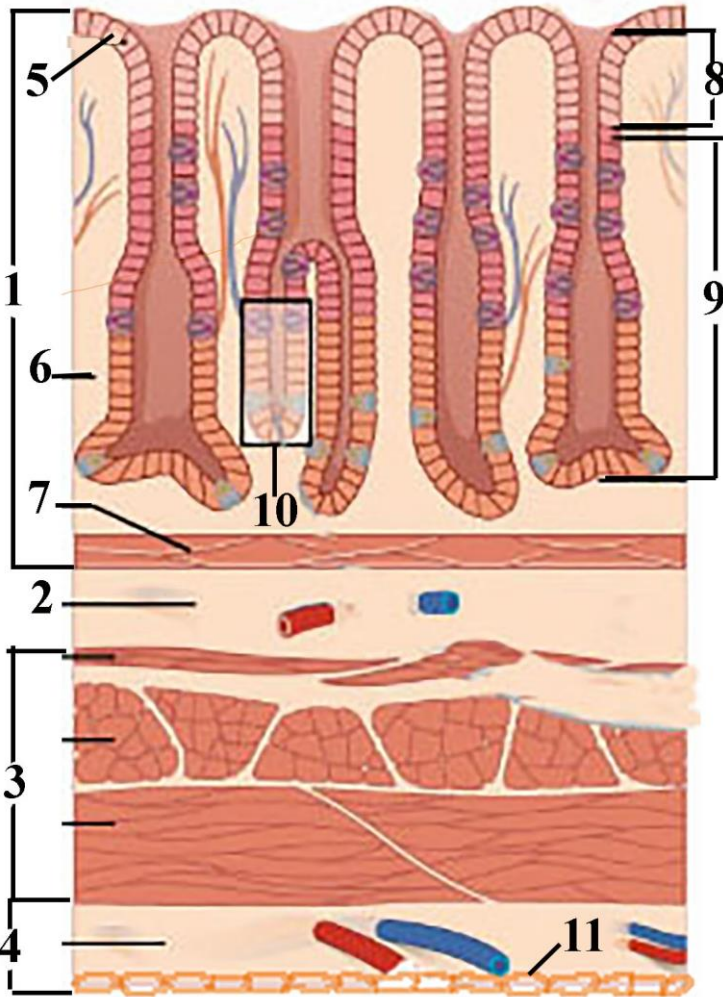




**Figure 21.2. Schematic drawing of esophago-gastric junction epithelium .**

1. Nonkeratinized stratified squamous epithelium of esophageal mucosa
2. Superficial cells
3. Basal cells
4. Lamina propria of mucosa.
5. Simple columnar epithelium of gastric mucosa
6. Lumen of cardiac glands of gastric mucosa

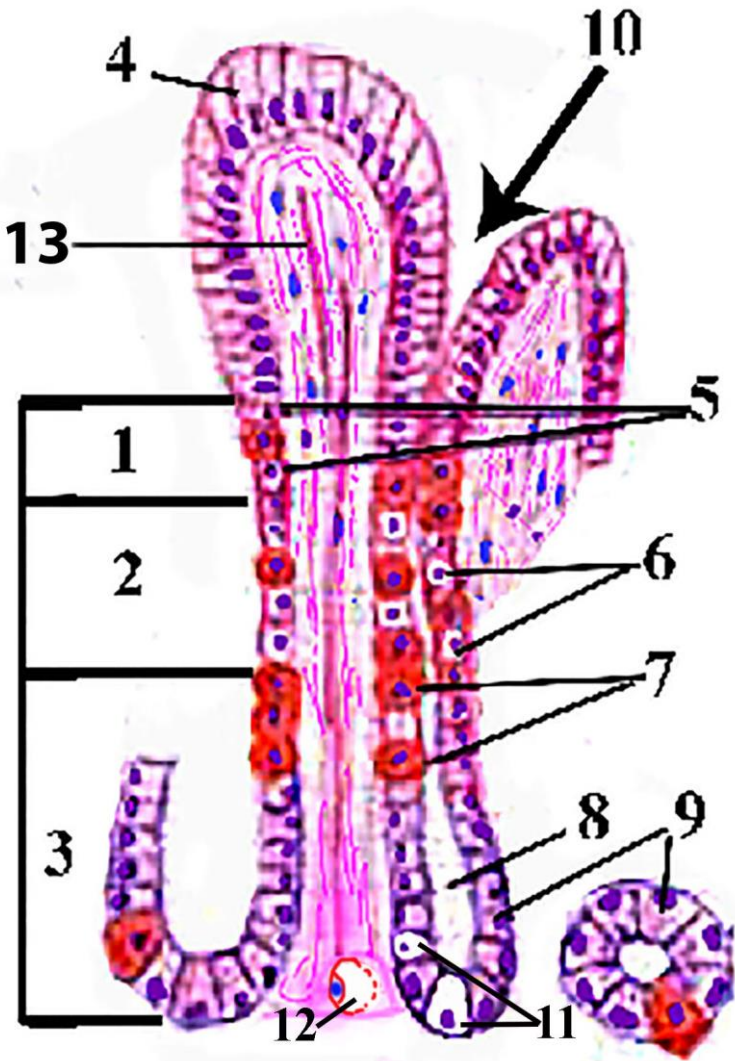




**Figure 21.3. Schematic drawing of structural elements of fundus of stomach.**

- 1. Mucosa**
- 2. Submucosa**
- 3. Muscularis externa**
- 4. Serosa**
- 5. Simple columnar epithelium of mucosa - surface mucous cells**
- 6. Lamina propria of mucosa**
- 7. Muscularis mucosae**
- 8. Gastric pit**
- 9. Gastric gland**

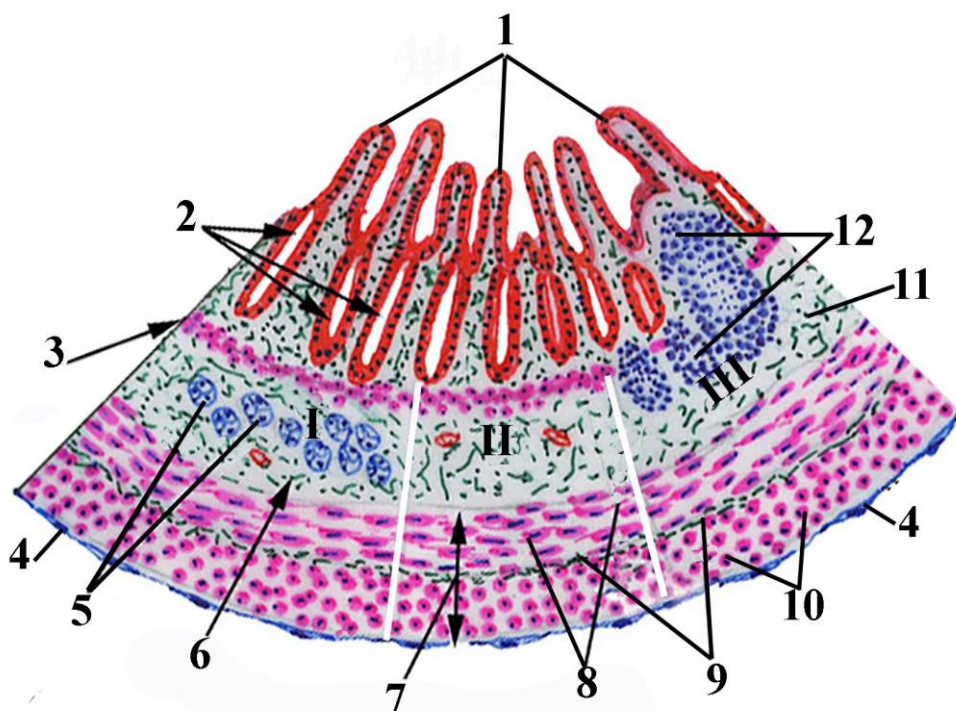
- 10. Base of gastric gland
- 11. Mesothelial cells of serosa



**Şəkil 21.4.                    Рисунок 21.4.                    Figure 21.4.**  
**Schematic representation of microscopic structure of fundic gland.**

1. Isthmus of fundic glands
2. Neck of fundic glands
3. Base of fundic glands
4. Simple columnar epithelium of mucosa (mucosal epithelium), surface mucous cells
5. Stem cells located in isthmus of fundic gland
6. Mucous neck cells of fundic gland
7. Parietal cell
8. Lumen of gland
9. Chief (zymogenic )cells
10. Gastric pit
11. Enteroendocrine cells
12. Visceral (fenestrated) type capillary
13. lamina propria of the gastric mucosa



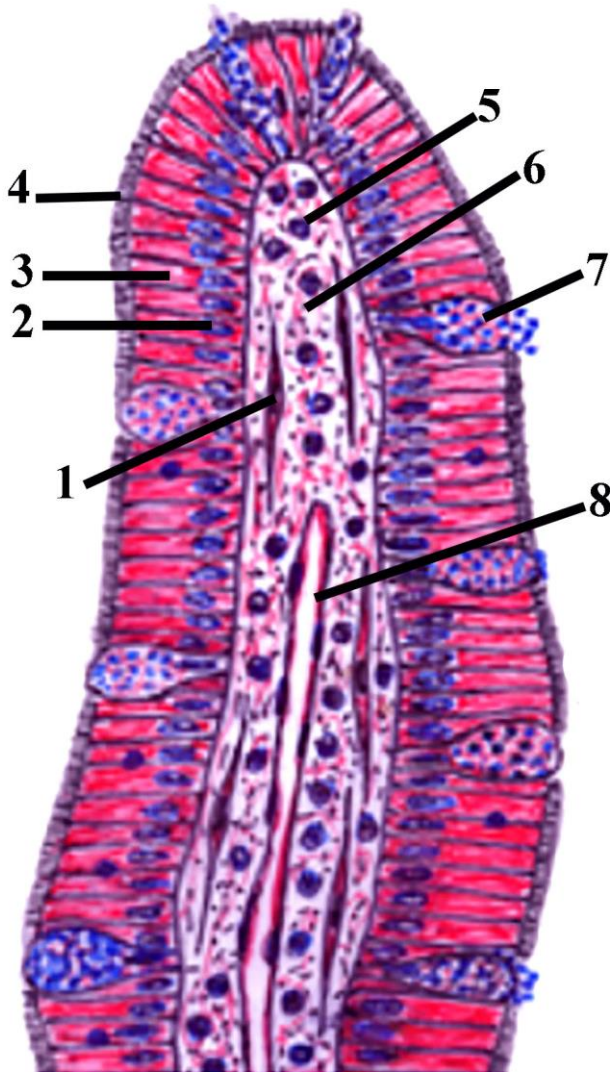


Şəkil 22.1. Рисунок 22.1. Figure 22.1.  
Schematic drawing of general structure of small intestine.

I - Duodenum; II – Jejunum; III – Ileum

1. Villi
2. Small intestinal glands (crypts)
3. muscularis mucosa
4. Mesothelial cells of serosa
5. Duodenal submucosal (Brunner's) glands
6. Connective tissue elements of submucosa
7. Muscular layer
8. Inner circular smooth muscle cells of muscular layer
9. Myenteric neural plexus

- 10. Outer longitudinal smooth muscle cells of muscular layer
- 11. Submucosa
- 12. Lymphoid nodules located in the submucosa of ileum (Peyer's patch)



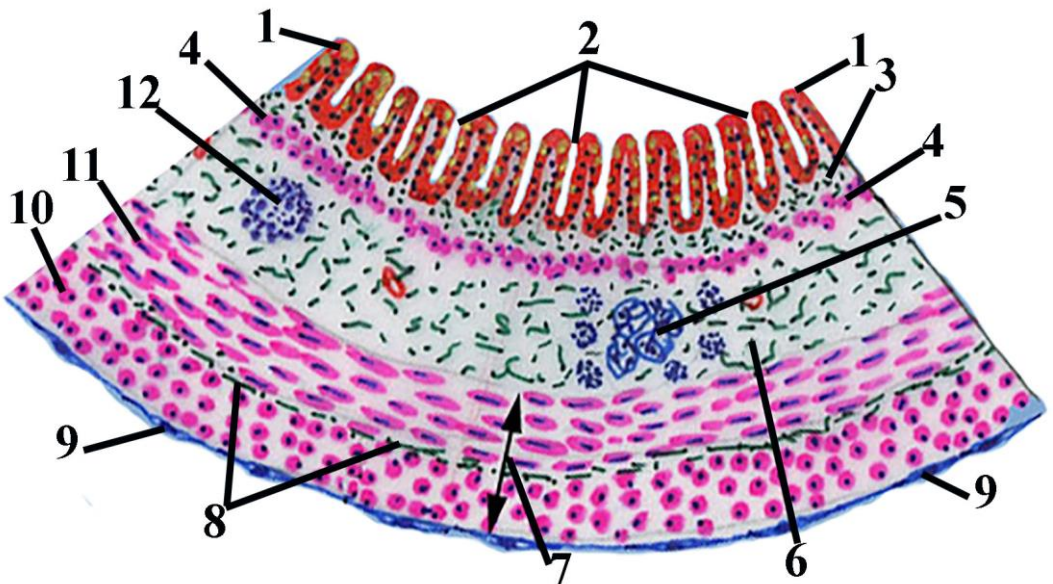
Şəkil 22.2.

Рисунок 22.2.

Figure 22.2.

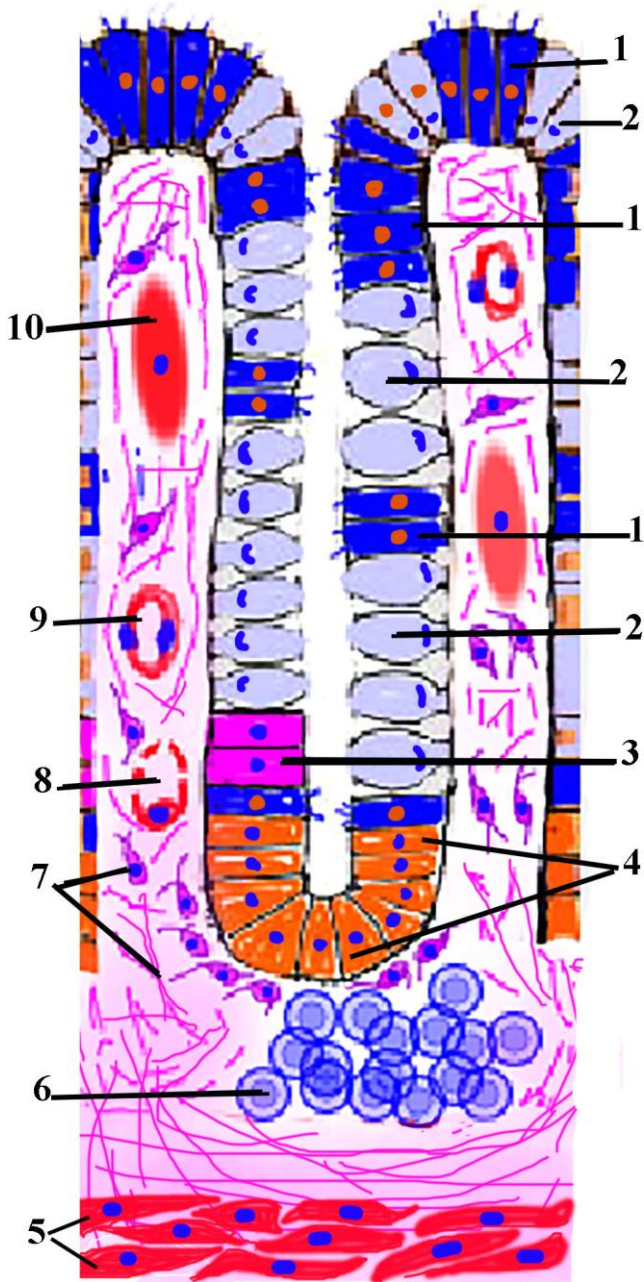
**Schematic drawing of microscopic structure of small intestinal villus.**

1. Smooth muscle cells located in lamina propria
2. Nucleus of simple columnar epithelial cell (enterocyte)
3. Cytoplasm of simple columnar epithelial cell
4. Striated border
5. Lymphocytes located in lamina propria
6. Connective tissue elements of lamina propria
7. Goblet cells
8. lacteal – lymph capillaries



**Şəkil 22.3.                    Рисунок 22.3.                    Figure 22.3.**  
**Schematic representation of general structure of large intestine.**

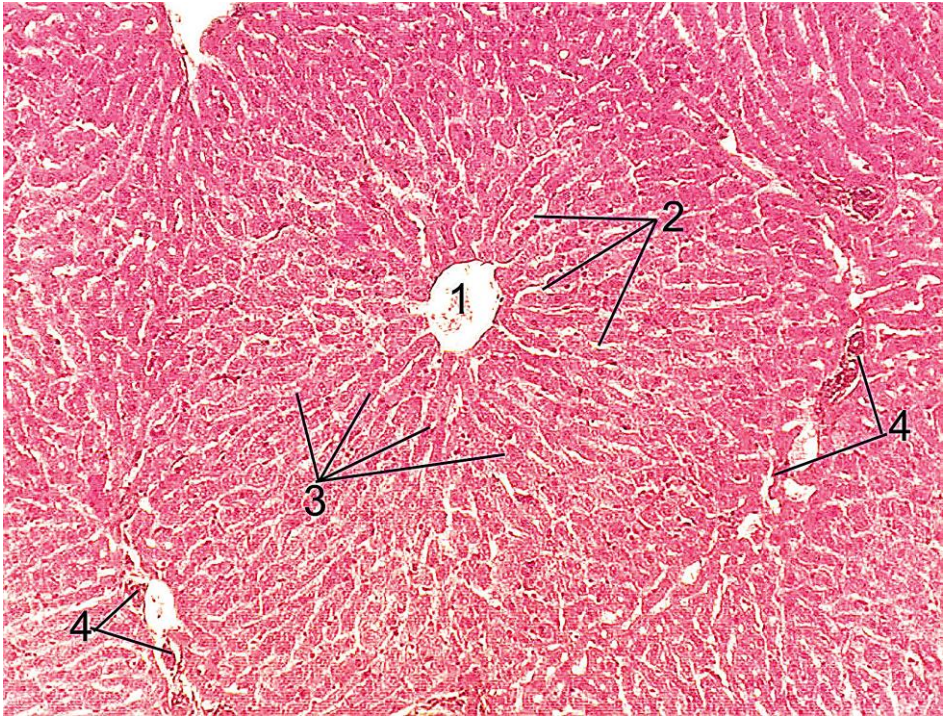1. Simple columnar epithelial cell (colonocyte)
2. Large intestinal glands (crypts)
3. Lamina propria of mucosa
4. Muscularis mucosa
5. Neural plexus of submucosa (Meissner plexus)
6. Submucosa
7. Muscular layer
8. Myenteric neural plexus
9. Mesothelial cells of serosa
10. Outer longitudinal layer of smooth muscle cells
11. Inner circular layer of smooth muscle cells
12. Lymphoid nodules of submucosa





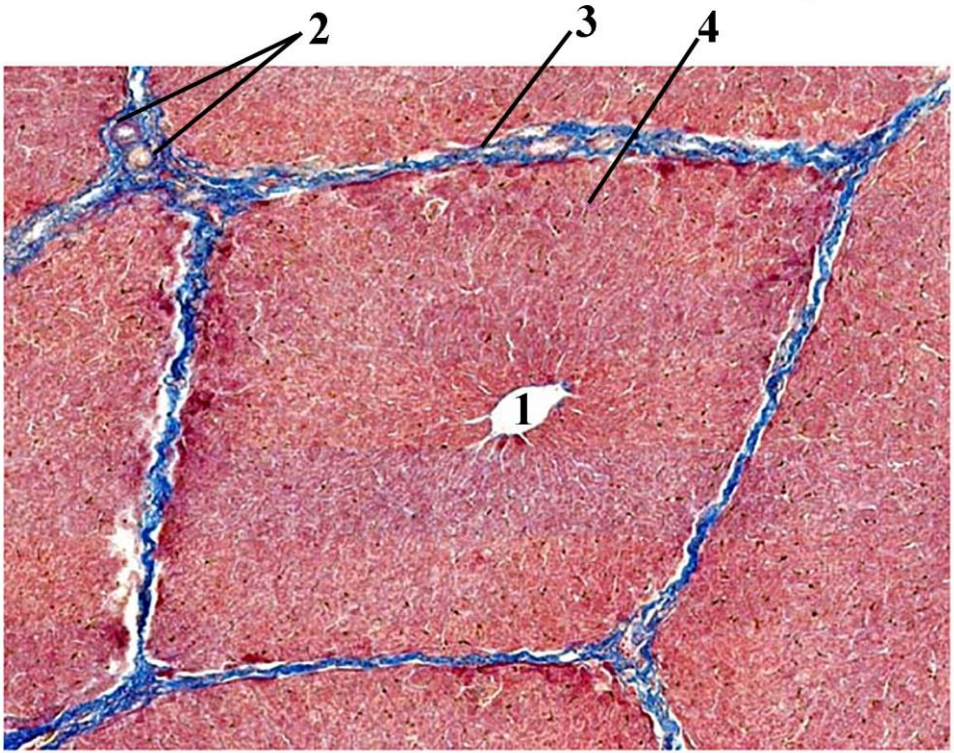
**Şəkil 22.4.                    Рисунок 22.4.                    Figure 22.4.**  
**Schematic drawing of structural elements(crypts) of large intestine.**

1. Simple columnar epithelium (enterocyte). The epithelial cells that lining the lumen of the large intestine know as **surface cells**,that lining glands know as **crypt enterocytes**
2. Goblet cells (exocrinocytes)
3. Epithelial stem cells
4. Enterocytes of intestinal crypt's base
5. Muscularis mucosa
6. Lymph nodules located in lamina propria
7. Connective tissue elements of lamina propria
8. Capillary
9. Arteriole
10. Smooth muscle cell



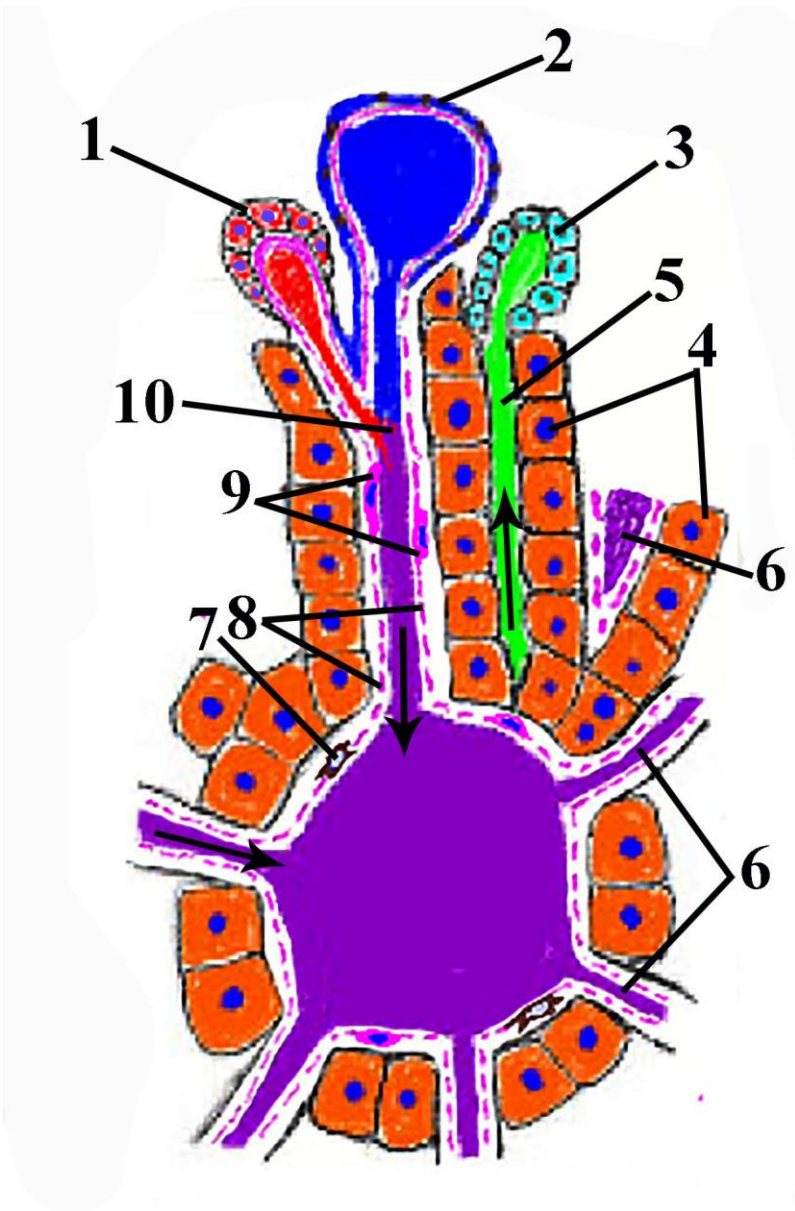
**Şəkil 23.1.            Рисунок 23.1.            Figure 23.1.**  
**Microscopic structure of human hepatic lobule.**

- 1.central vein
- 2.liver sinusoids
- 3.liver plates
- 4.portal areas



**Şəkil 23.2.            Рисунок 23.2.            Figure 23.2.**  
**Microscopic structure of pig hepatic lobule**

- 1. Central vein
- 2. Portal area
- 3. Interlobular connective tissue elements
- 4. Liver plates



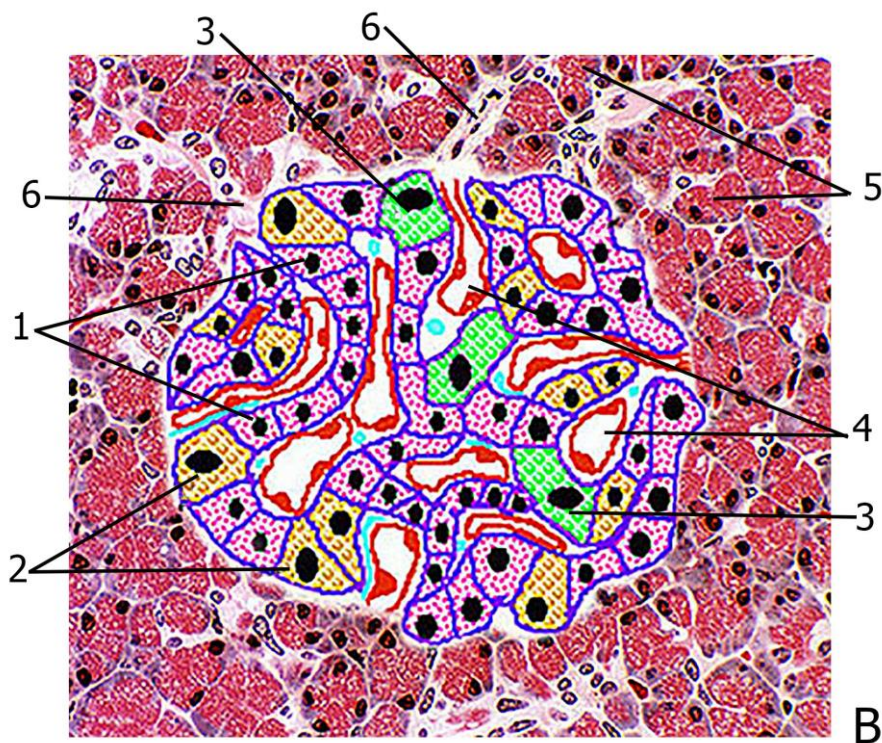
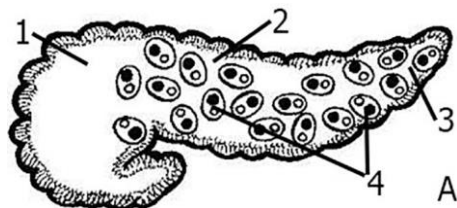
**Şəkil 23.3. Рисунок 23.3. Figure 23.3.**  
**Schematic representation interactions liver portal area elements with hepatocytes and central vein.**

- 1.interlobular artery (branch of hepatic artery)
- 2.interlobular vein(branch of portal vein)
- 3.interlobular bile duct
- 4.liver plates



5. bile canaliculi
6. sinusoids
7. Kupffer cells
8. peripheral part of endothelium of the sinusoid
9. central part of endothelial cell of sinusoid
10. mixing area of arterial and venous blood
11. central vein





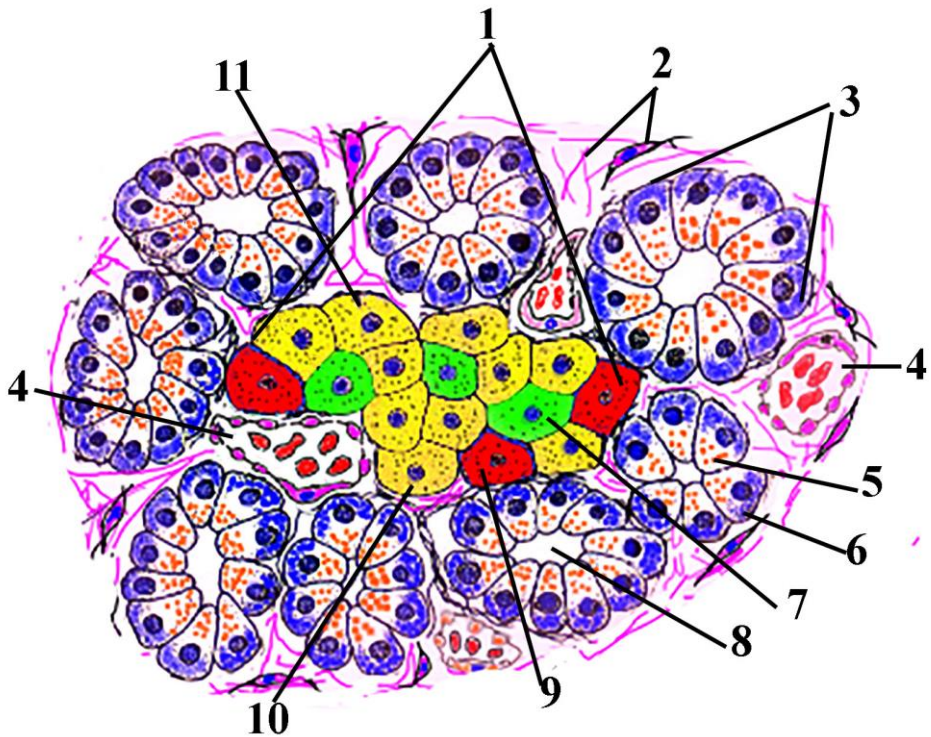
Şəkil 24.1. Рисунок 24.1. Figure 24.1.  
Schematic representation of exocrine and endocrine parts of pancreas

A.1.head of pancreas

- 2. body of pancreas
- 3. tail of pancreas
- 4. islets of Langerhans

B.

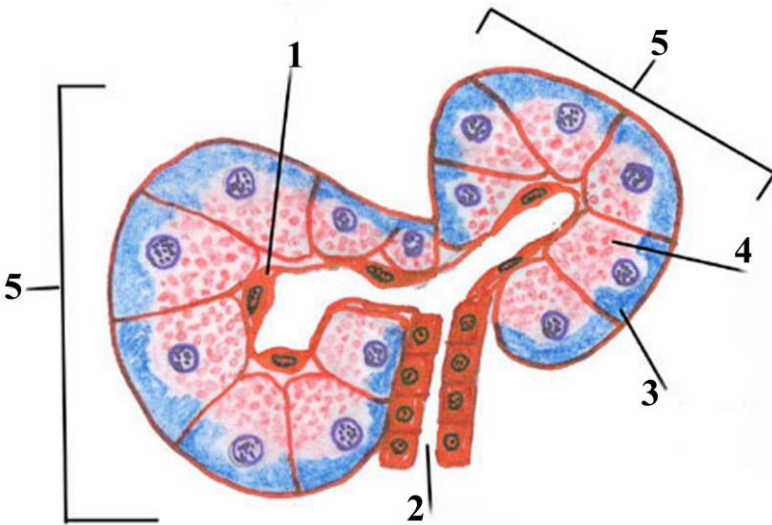
- 1. B( $\beta$ )-endocrinocytes (insulin secretory cells)
- 2. A( $\alpha$ )-endocrinocytes (glucagon secretory cells)
- 3. D( $\delta$ )-endocrinocytes (somatostatin secretory cells)
- 4. sinusoid type venules
- 5. exocrine part of pancreas (acinus)
- 6. connective tissue elements



Şəkil 24.2. Рисунок 24.2. Figure 24.2.  
 Schematic representation exocrine and edocrine parts of pancreas.

- 1. islet of Langerhans

- 2.connective tissue elements
- 3.acinus of pancreas
- 4.sinusoid type vessels
- 5.apical part of exocrine cell
- 6.basal part of exocrine cell
- 7.D( $\delta$ )-endocrinocytes
- 8.lumen of acinus
- 9.A( $\alpha$ )-endocrinocytes
10. and 11B( $\beta$ )- endocrinocytes

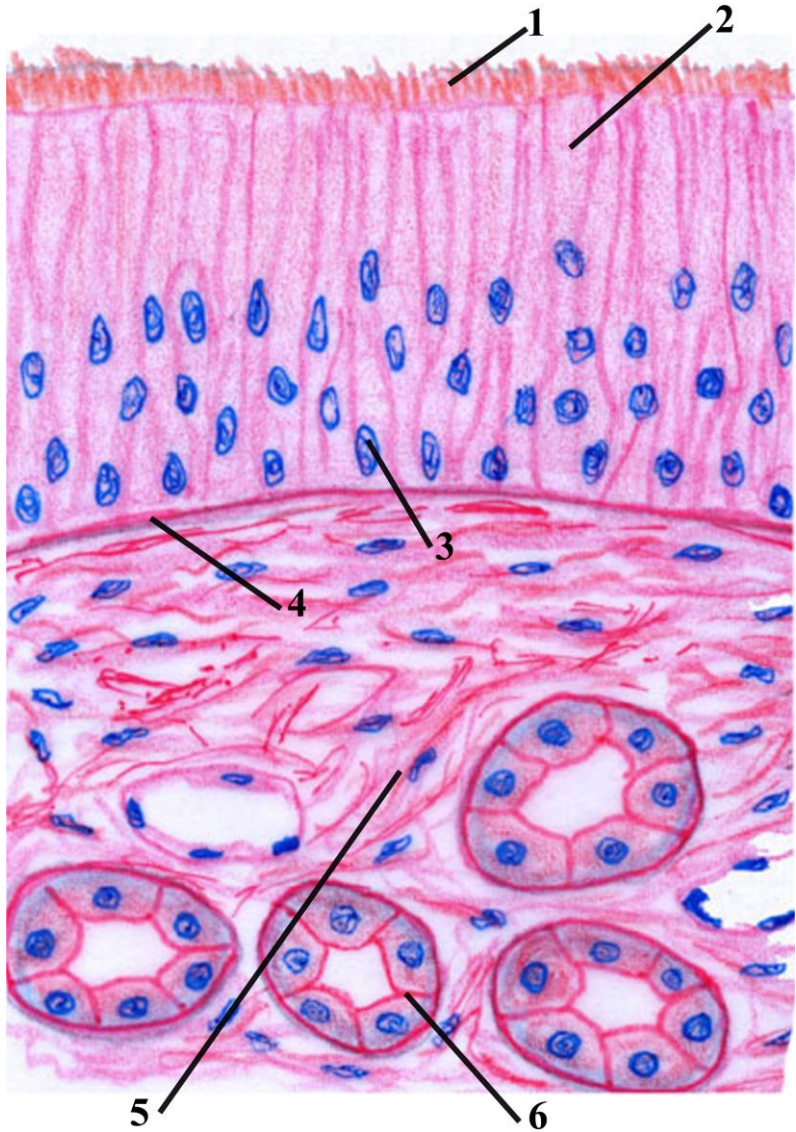


**Şəkil 24.3. Рисунок 24.3. Figure 24.3.**

**Microscopic representation of exocrine part of pancreas**

1. centroacinar cells
2. intercalated duct
3. homogenous part of exocrinocyte
4. Zimogen part of exocrinocyte
5. acinus

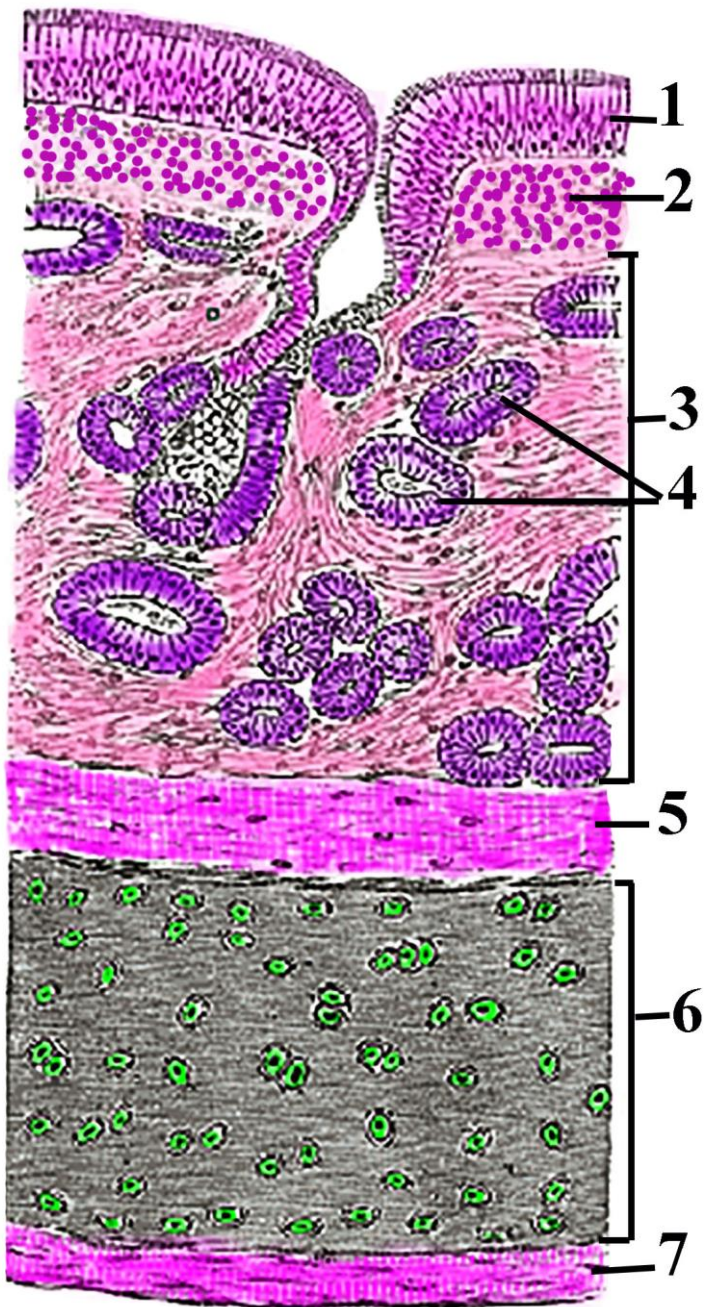




**Şəkil 25.1.            Рисунок 25.1.            Figure 25.1.**  
**Schematic drawing of respiratory mucosa of nasal cavity.**

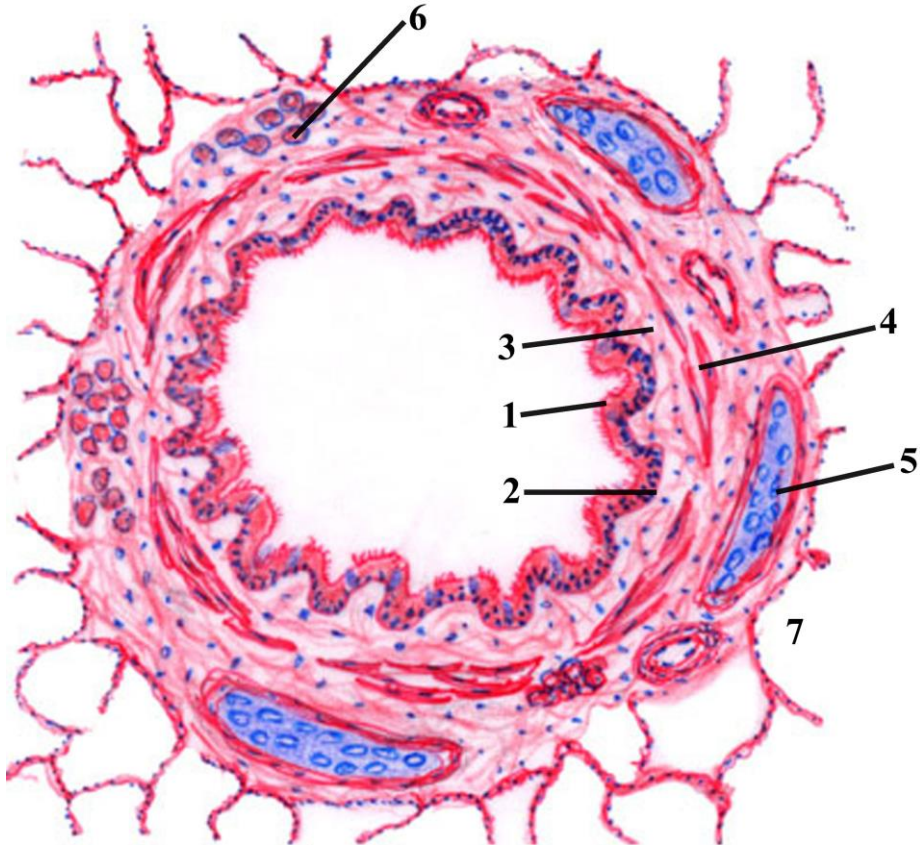
- 1. Cilia**
- 2. Ciliated epithelial cells**
- 3. Basal cell**
- 4. Basement membrane**
- 5. Lamina propria**
- 6. Secretory portion of gland**





Şəkil 25.2. Рисунок 25.2. Figure 25.2.  
Schematic representation of structure of tracheal wall.

- 1. Pseudostratified ciliated columnar epithelium**
- 2. Elastic fibers (elastic lamina)**
- 3. Submucosa**
- 4. Mucous and seromucous glands**
- 5. Fibromuscular layer**
- 6. C - cartilage of the adventitial layer**
- 7. Adventitial layer**



Şəkil 26.1.            Рисунок 26.1.            Figure 26.1.  
 Schematic representation of medium diameter bronchi.  
 Microscopic view

1 mucus secretion over the wall ( internal side)

2 respiratory mucosa

3 lamina propria of mucosa layer

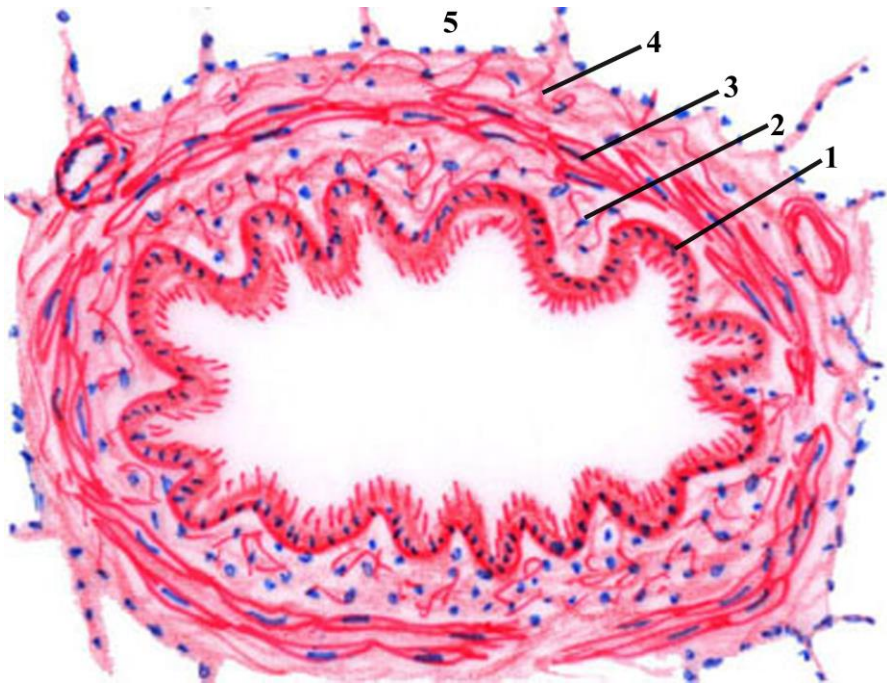
4 muscular lamina of mucosa layer

5 cartilage island

6 glands of bronchi

7 alveoli

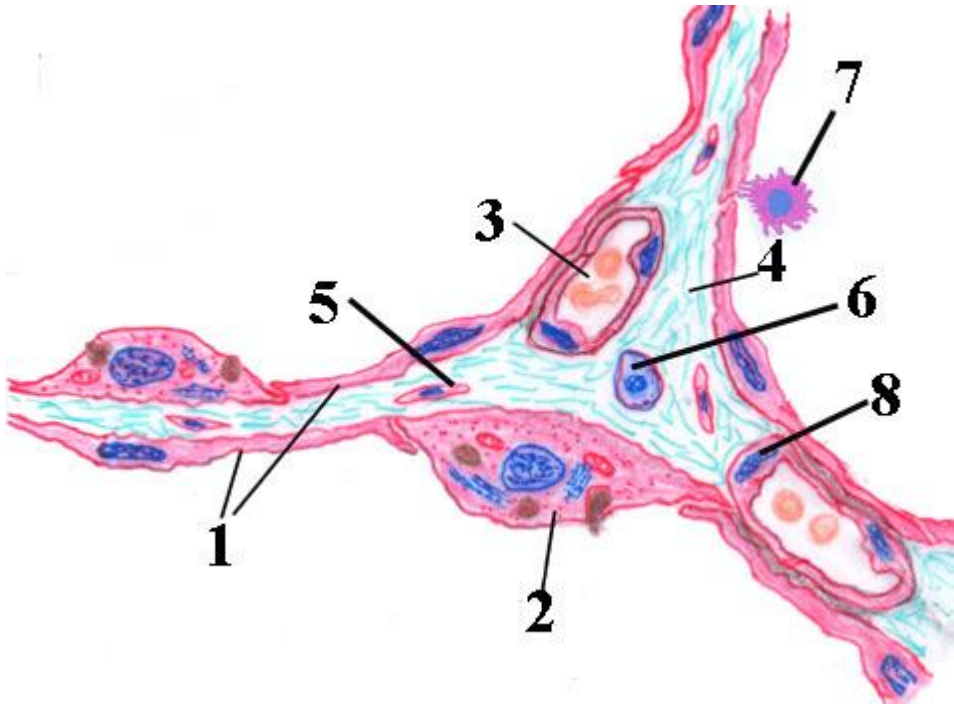




**Şəkil 26.2.            Рисунок 26.2.            Figure 26.2.**  
**Schematic drawing of microscopic structure of bronchiole.**

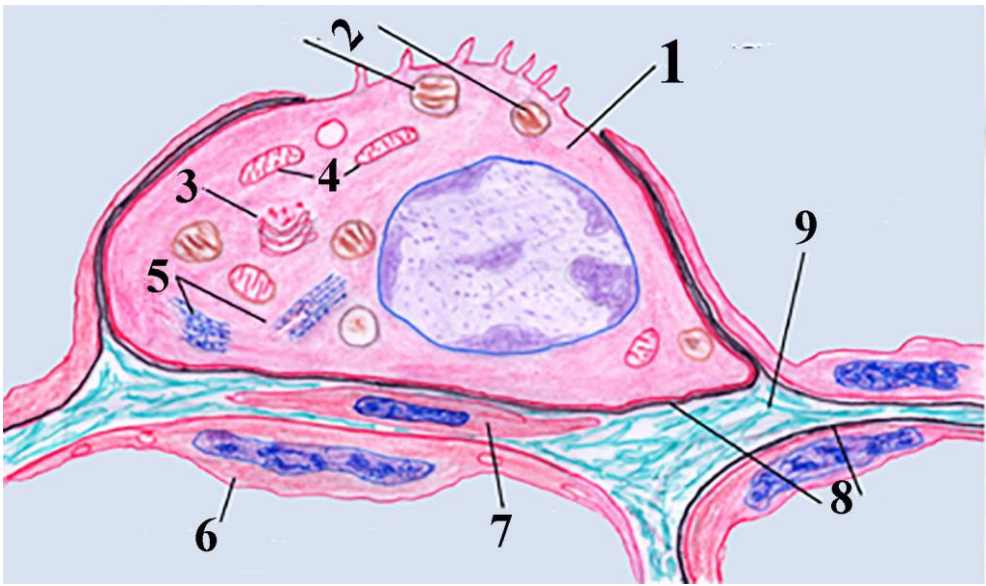
- 1. Respiratory epithelium**
- 2. Lamina propria of mucosa**
- 3. Muscularis mucosa**
- 4. Adventitia**
- 5. Alveoli**





**Şəkil 26.3.            Рисунок 26.3.            Figure 26.3.**  
**Scheme on microscopic view of alveoli and structures surrounding it.**

- 1 I type alveolar cell**
- 2 II type alveolar cells**
- 3 blood vessels - capillary**
- 4 alveolar septum**
- 5 fibroblasts**
- 6 mast cell in alveolar septum**
- 7 macrophage in alveolar lumen**
- 8 endothelial cells**



**Şəkil 26.4.            Рисунок 26.4.            Figure 26.4.**  
**Schematic drawing of type II alveolar cell, surrounded it structures.**

- 1. Type II alveolar cell**
- 2. Lamellar bodies that contain pulmonary surfactant**
- 3. Golgi complex**
- 4. Mitochondria**
- 5. Rough endoplasmic reticulum**
- 6. Type I alveolar cell**
- 7. Fibrocyte**
- 8. Basal lamina**
- 9. Fibrous elements of connective tissue**

## **Referat için**

## Referat için

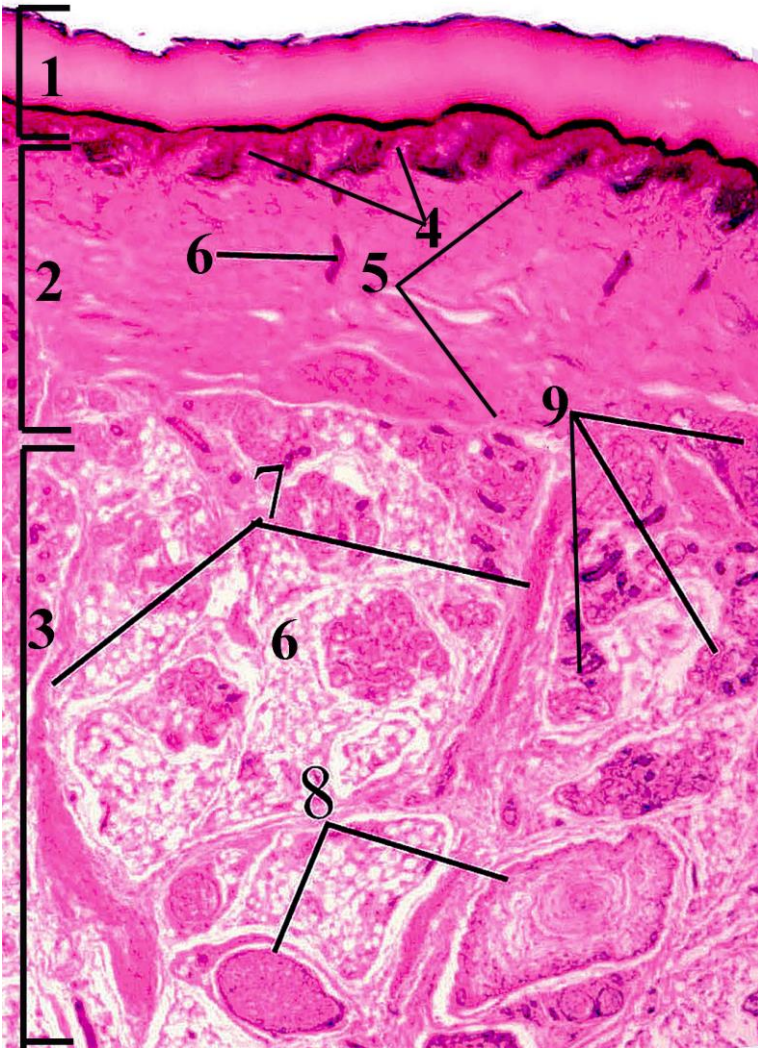
## **Referat için**



## Referat için

## Referat için

II quiz	27
Skin	28



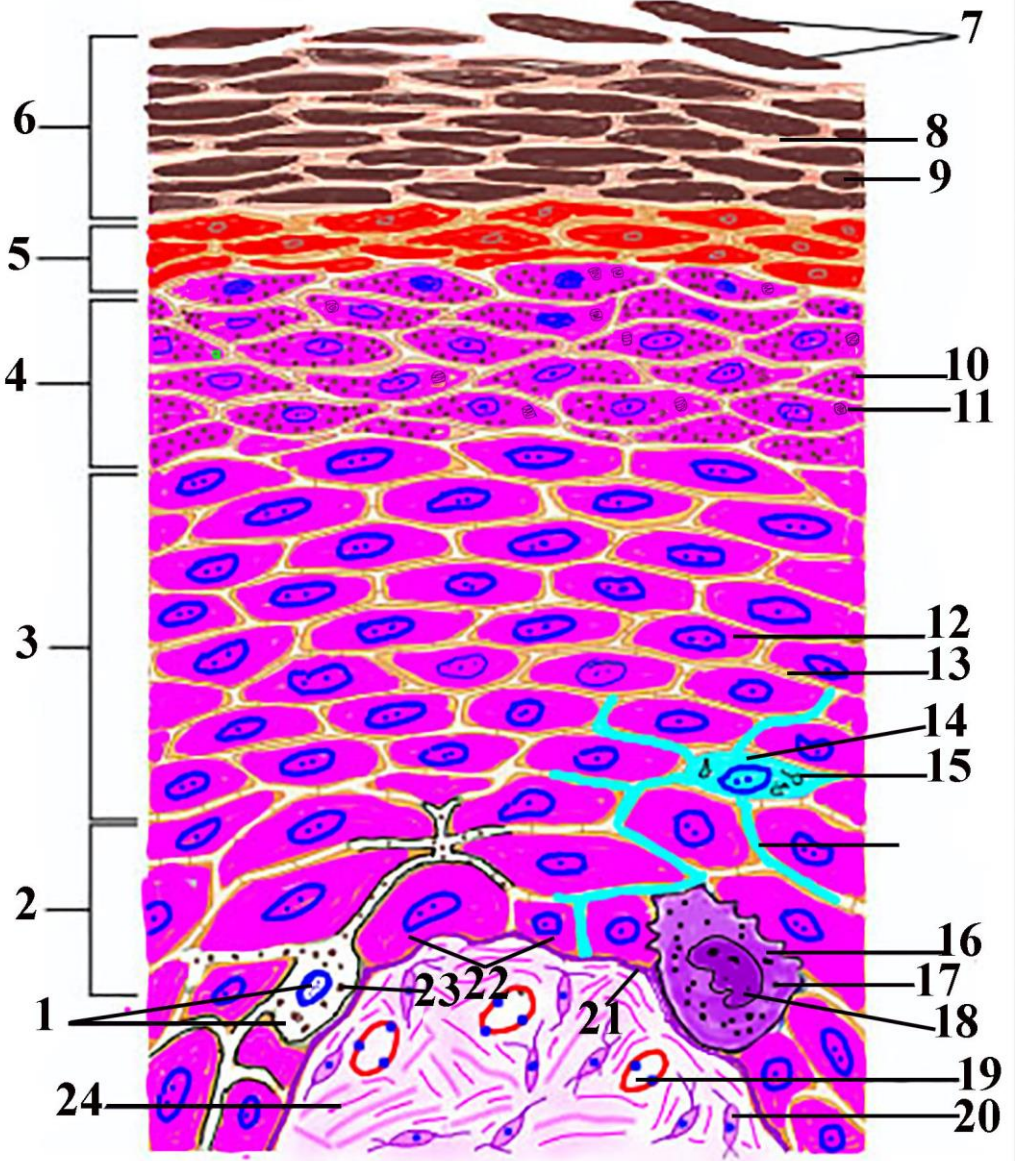
Şəkil 28.1.

Рисунок 28.1.

Figure 28.1.

## **Photomicrograph of skin. Stain hematoxylin eosin.**

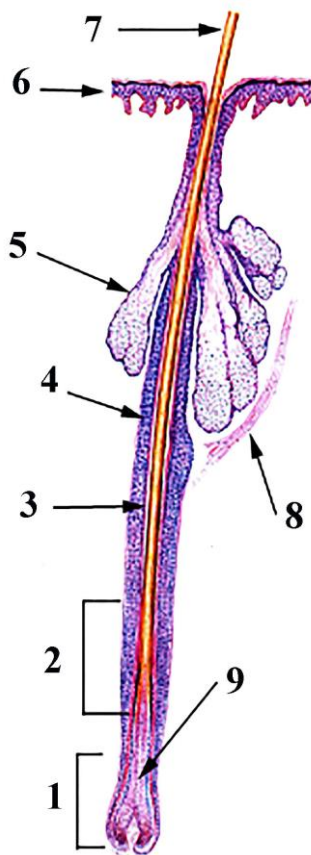
- 1. Epidermis**
- 2. Dermis**
- 3. Hypodermis (subcutaneous tissue)**
- 4. Papillary layer of the dermis**
- 5. Reticular layer of the dermis**
- 6. Duct of sweat glands**
- 7. Skin ligaments (retinaculum cutis)**
- 8. Pacinian corpuscles**
- 9. Sweat glands**



**Şəkil 28.2.                    Рисунок 28.2.                    Figure 28.2.**  
**Schematic representation of layer and cellular composition**  
**of epidermis**

- 1. Melanocyte**
- 2. Stratum basale, basale cells layer, germinative layer**
- 3. Stratum spinosum**
- 4. Stratum granulosum**
- 5. Stratum lucidum**
- 6. Stratum corneum**
- 7. Desquamated cells**
- 8. Intercellular matrix**
- 9. Squames– corneocytes**
- 10. Keratohyalin granules**
- 11. Membrane-coating granules (lamellar bodies)**
- 12. Prickle cells (keratinocyte)**
- 13. Desmosomes**
- 14. Dendritic cells (Langerhans cells)**
- 15. Ping pong paddles shaped (Birbeck) granules**
- 16. Merkel cells**
- 17. Secretory granules**
- 18. Nucleus of merkel cell**
- 19. Blood vessel**
- 20. Fibrocyte**
- 21. Basal membrane**
- 22. Basal cells (keratinocytes)**
- 23. Melanosomes**
- 24. Bundles of collagen fibers located in papillary layer**
- 25. Process of Langerhans cell**





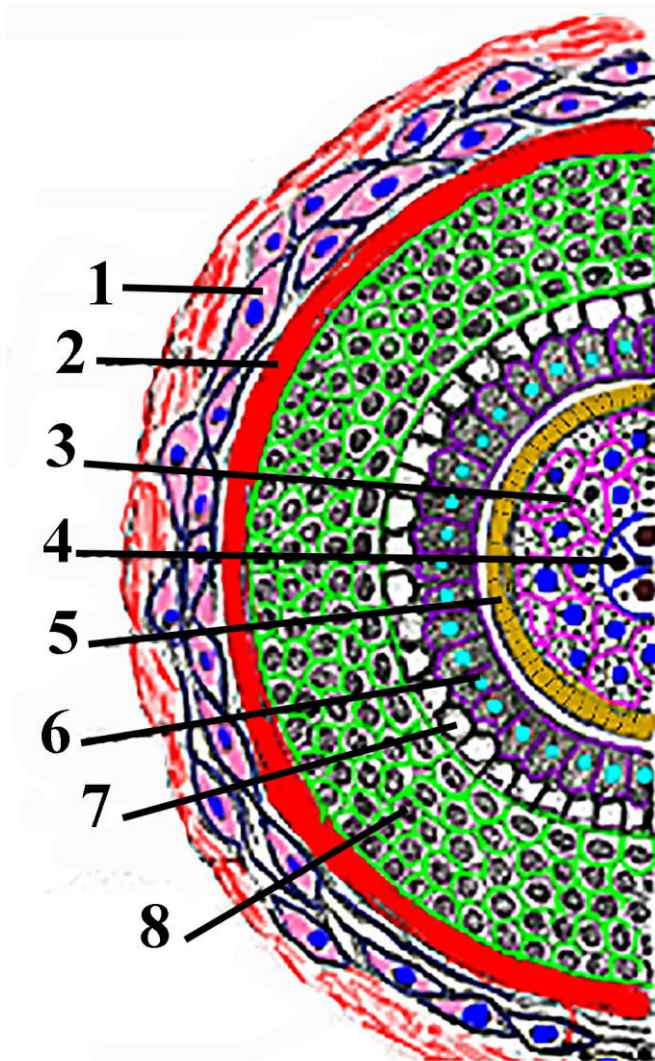
Şəkil 29.1.

Рисунок 29.1.

Figure 29.1.

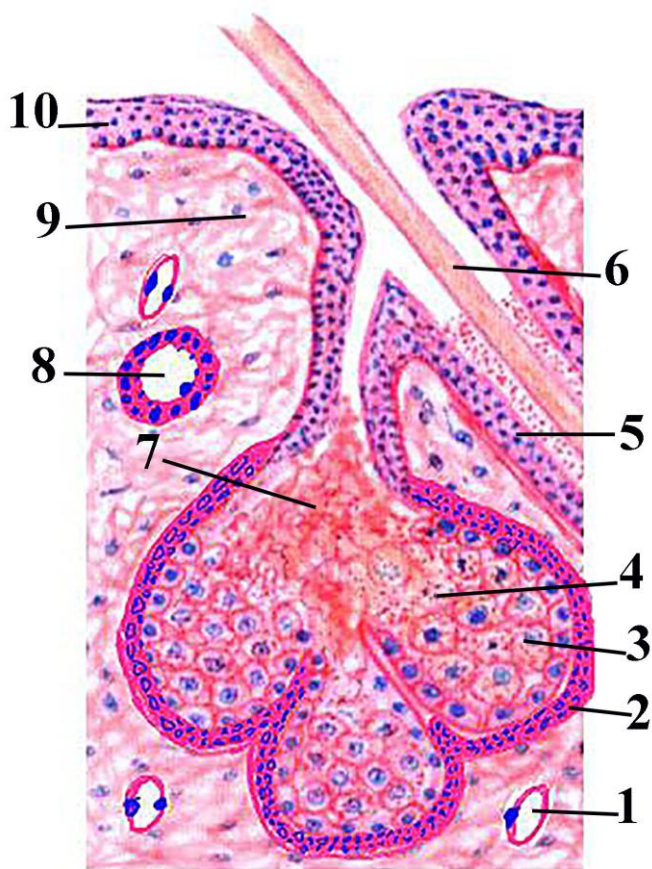
Schematic representation of hair.

1. Hair bulb
2. Formation and elongation part of internal root sheath of hair
3. Internal root sheath
4. External root sheath
5. Sebaceous gland
6. Epidermis
7. Hair shaft
8. Arrector pili muscle
9. Formation area of hair cortex



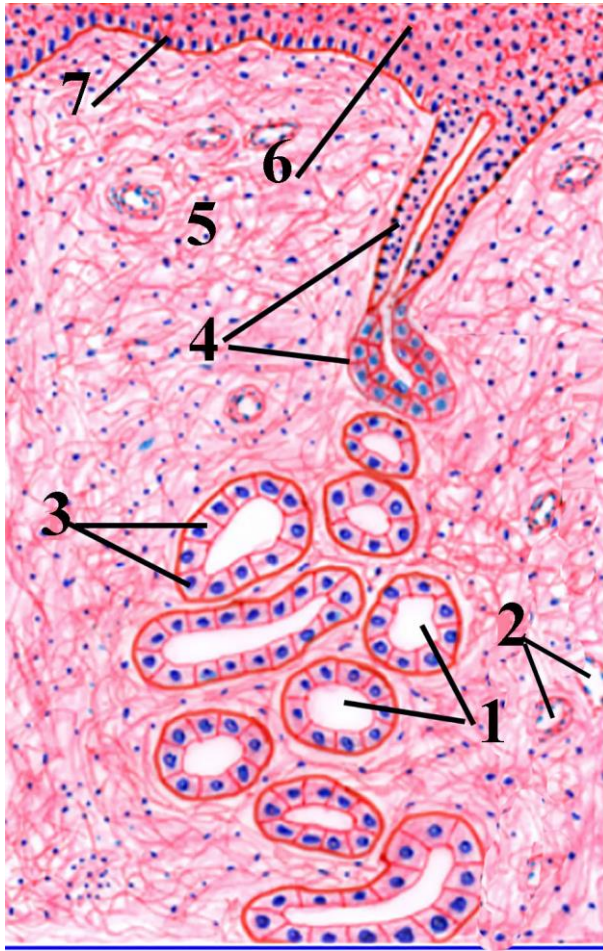**Şəkil 29.2.                      Рисунок 29.2.                      Figure 29.2.**  
**Schematic representation of transional section of upper part of hair root.**

1. Fibrous (connective tissue) sheath
2. Glassy membrane
3. Hair cortex
4. Hair medulla
5. Cuticle
6. Huxley's layer
7. Henley's layer
8. External root sheath



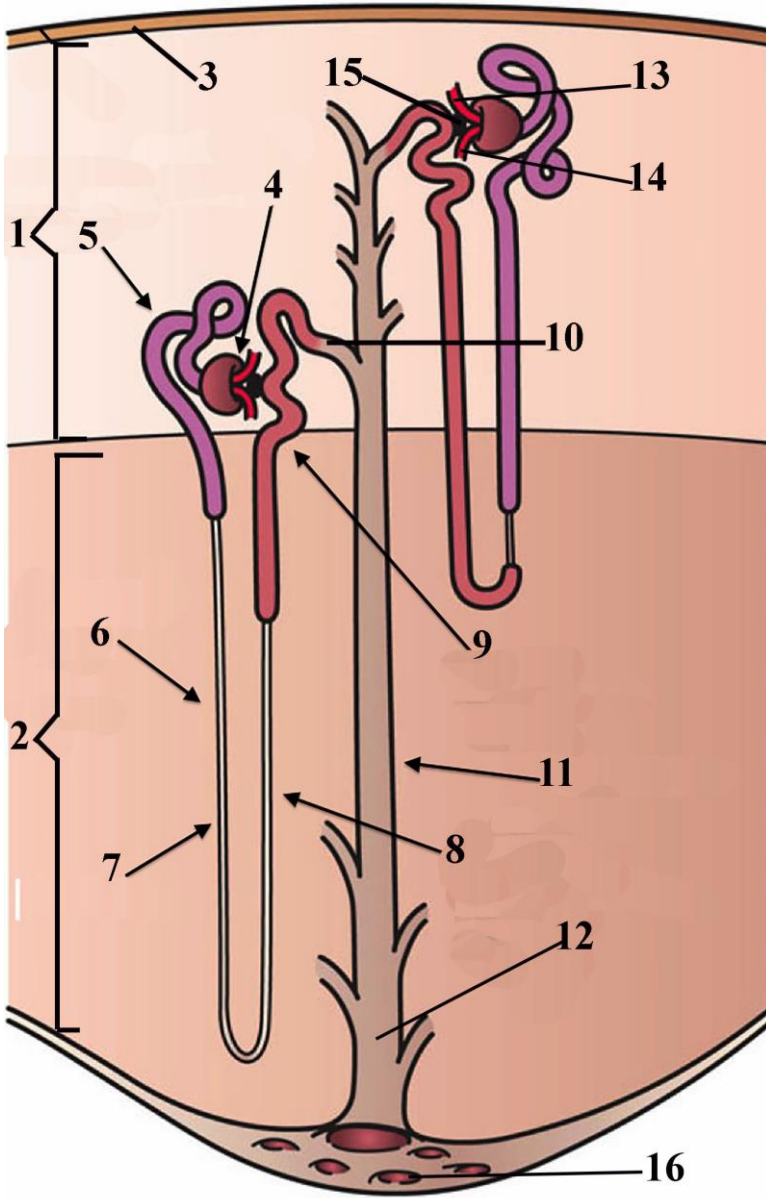
**Şəkil 29.3. Рисунок 29.3. Figure 29.3.**  
**Schematic representation of sebaceous gland and surrounded structures.**

1. Blood vessel
2. Stem cells layer located on the basal membrane
3. Sebocytes
4. Destroyed sebocytes
5. External root sheath
6. Hair cortex
7. Formated sebum
8. Duct of sweat gland
9. Connective tissue elements
10. Epidermis



**Şəkil 29.4.                      Рисунок 29.4.                      Figure 29.4.**  
**Schematic representation of duct of sweat gland.**

1. Lumen of duct
2. Blood vessels
3. Epithelial layer of duct
4. Opening of duct
5. Connective tissue elements of the dermal papilla
6. Stratum spinosum of epidermis
7. Stratum basale of epidermis



**Şəkil 30.1.**

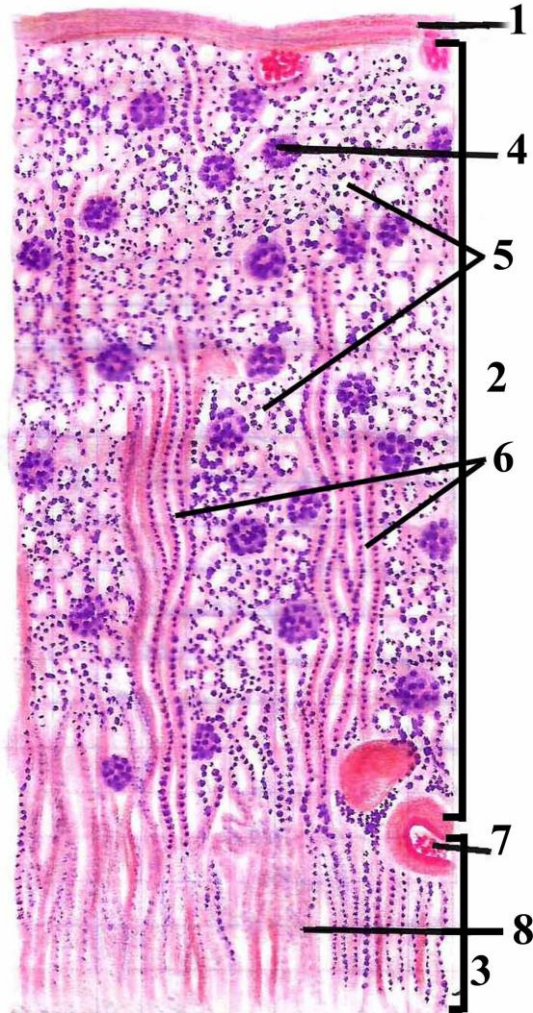
**Рисунок 30.1.**

**Figure 30.1.**

**Schematic representation of structural elements of kidney.**

1. Renal cortex
2. Renal medulla
3. Fibrous capsule
4. Renal corpuscle
5. Proximal convoluted tubule
6. Descending limb of Henle's (nephron) loop
7. Limb of Henle's (nephron)
8. Ascending limb of Henle's (nephron) loop
9. Distal convoluted tubule
10. Connecting tubule
11. Common collecting tubule
12. Papillary duct
13. Afferent arteriole
14. Efferent arteriole
15. Macula densa
16. area cribrosa



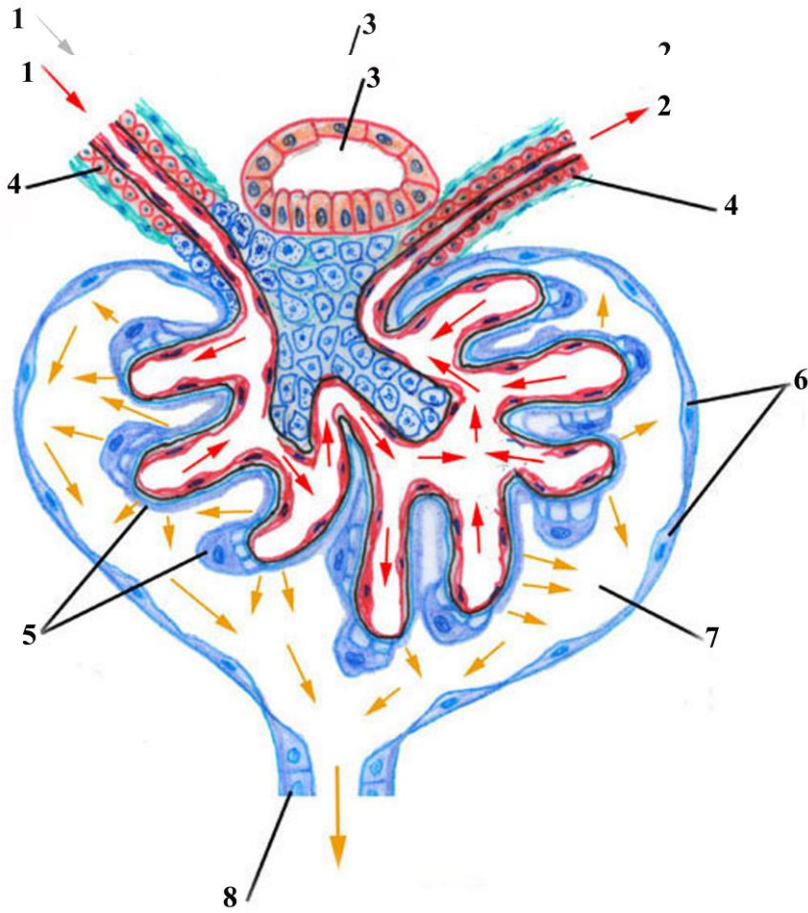


Şəkil 30.2. Рисунок 30.2.

Figure 30.2.

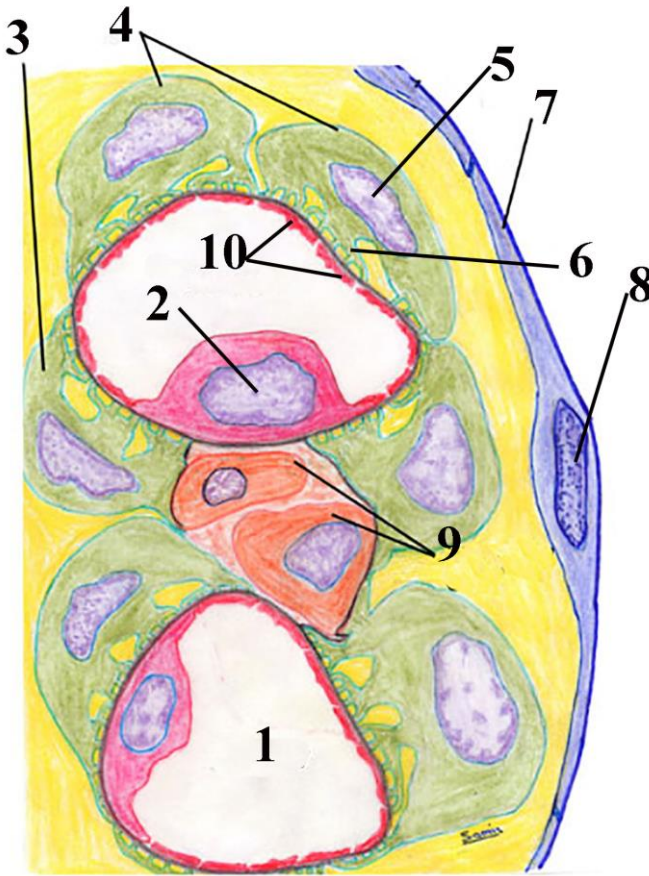
Microscopic structure of kidney capsule and cortex. Scheme.

1. Capsule
2. Cortex
3. Medulla
4. Renal corpuscle
5. Proximal and distal part of nephron
6. Medullary rays
7. Blood vessel
8. Rectal tubules



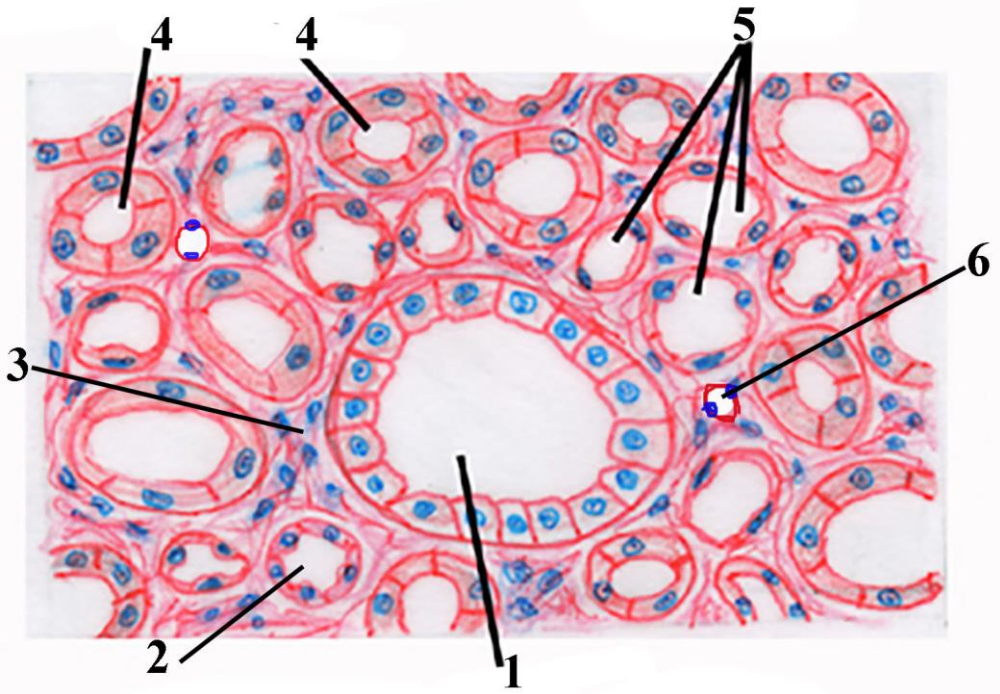
**Şəkil 30.3. Рисунок 30.3. Figure 30.3.**  
**Photomicrograph of renal corpuscle. Scheme.**

- 1. Afferent arteriole**
- 2. Efferent arteriole**
- 3. Distal convoluted tubule**
- 4. Smooth muscle cells**
- 5. Podocyte**
- 6. parietal layer of glomerular capsule**
- 7. urinary space**
- 8. Proximal convoluted tubule**



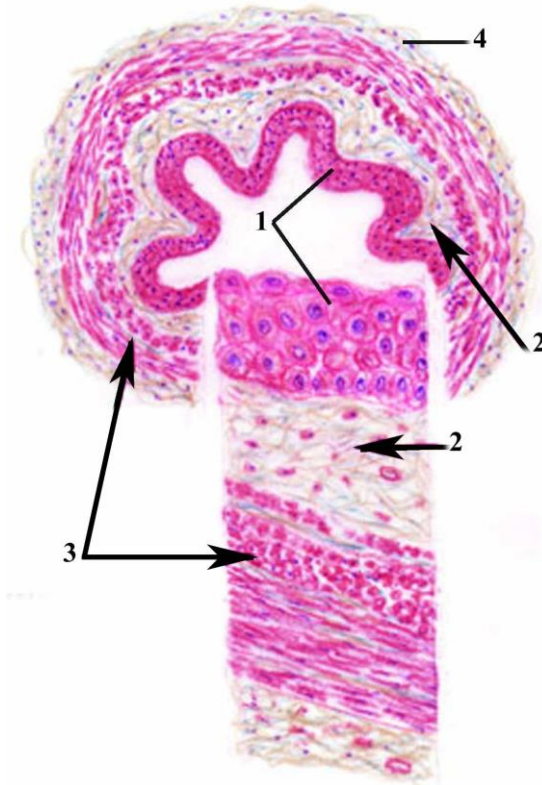
**Şəkil 30.4. Рисунок 30.4. Figure 30.4.**  
**Microscopic structure of glomerular capsule, podocytes, capillary and mesangial cells. Scheme.**

1. Lumen of glomerular capillaries
2. Central part of fenestrated endothelial cell
3. Cytotrabecules of podocytes (primary process)
4. Podocytes
5. Nucleus of podocyte
6. Pedicels of podocytes (secondary process)
7. Peripheral part of parietal cell of capsule
8. Central part of parietal cell of capsule
9. Mesangial cells
10. Peripheral part of fenestrated endothelial cell



**Şəkil 30.5.      Рисунок 30.5.      Figure 30.5**  
**Schematic representation of transitional section of renal medulla.**


1. Collecting tubules
2. Descending limbs of loop of Henle
3. Connective tissue elements of medulla
4. Descending part of proximal convoluted tubules
5. Thin descending limbs of Henle's loop
6. Capillary rectae



**Şəkil 31.1.      Рисунок 31.1.      Figure 31.1.**  
**Schematic representation of microscopic structure of ureter.**

1. Transitional epithelium of mucosa
2. Submucosa
3. Layers of muscularis externa
4. Adventitia

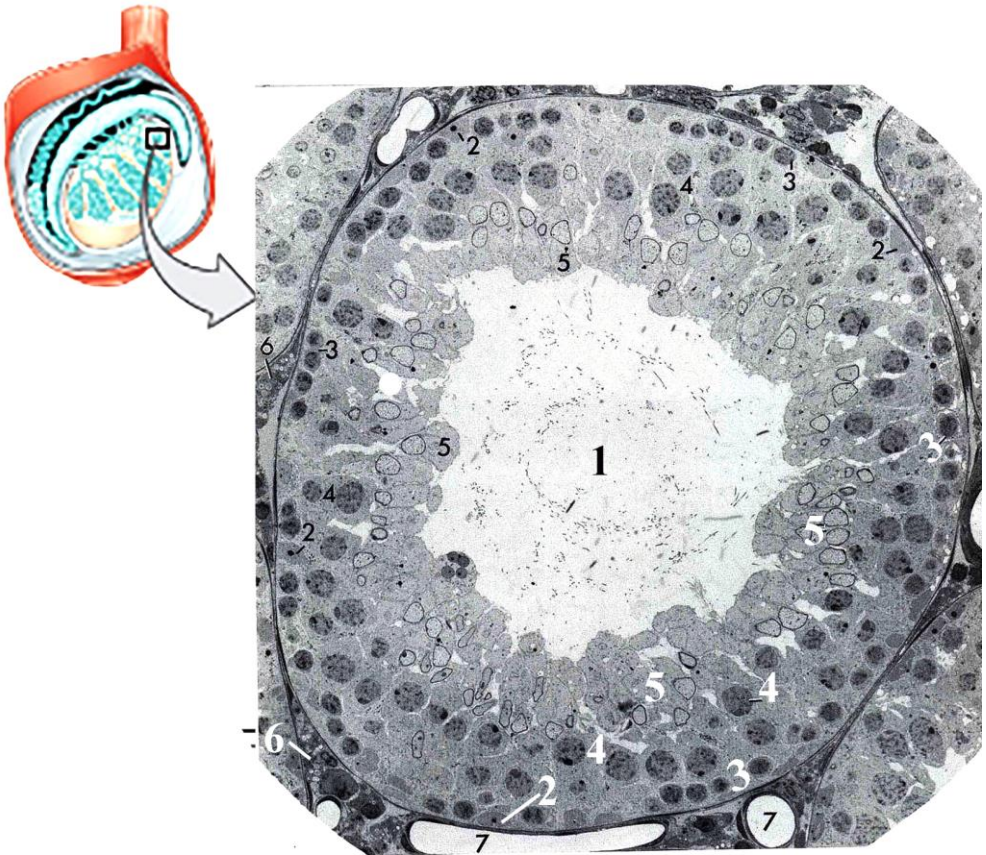




**Şəkil 31.2. Рисунок 31.2. Figure 31.2.**  
**Schematic drawing of histological structure of urinary bladder .**

1. Mucosa
2. Muscularis externa
3. Serosa
4. Mesothelium of serosa
5. Connective tissue layer of serosa
6. Outer longitudinal layer of muscularis externa
7. Circular layer of muscularis externa
8. Inner longitudinal layer of muscularis externa
9. Lamina propria
10. Transitional epithelium of mucosa
11. Basal layer
12. Intermediate layer
13. Binucleated cells of surface layer
14. Mononucleated cells of surface layer





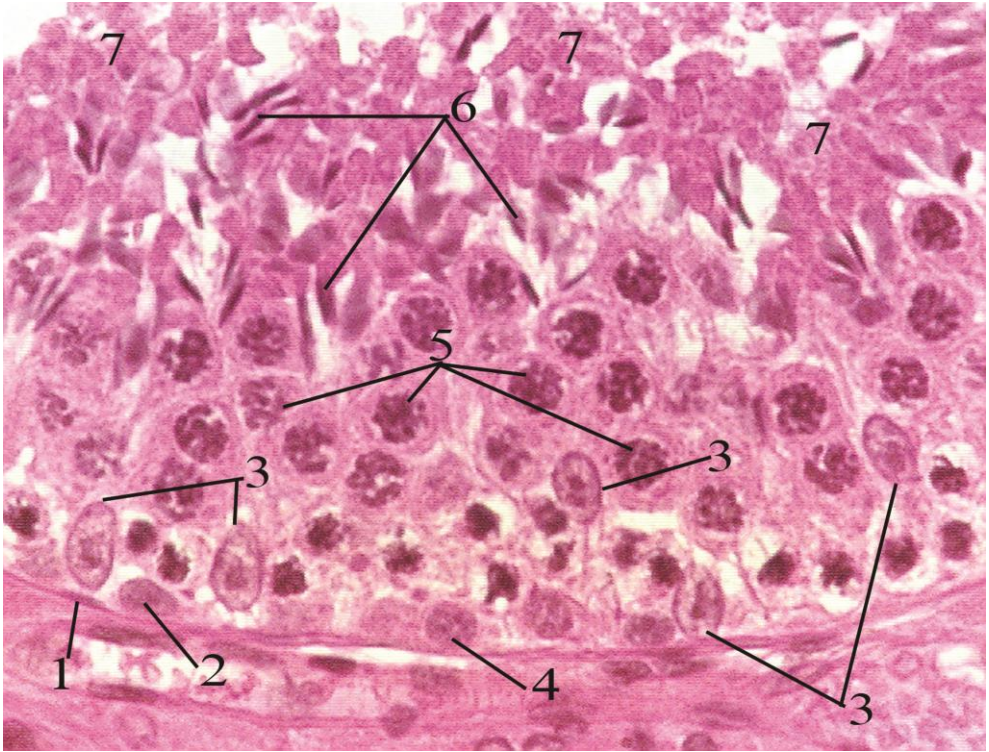
Şəkil 32.1.

Рисунок 32.1.

Figure 32.1.

**Electron micrograph of seminiferous tubule and surrounded it structures.**

1. Lumen of seminiferous tubule
2. Sertoli cells
3. Spermatogonia
4. Primary spermatocytes (in pachythen stage of I meiotic prophase)
5. Early spermatids
6. interstitial endocrine (Leydig) cell
7. Peritubular capillaries and venules



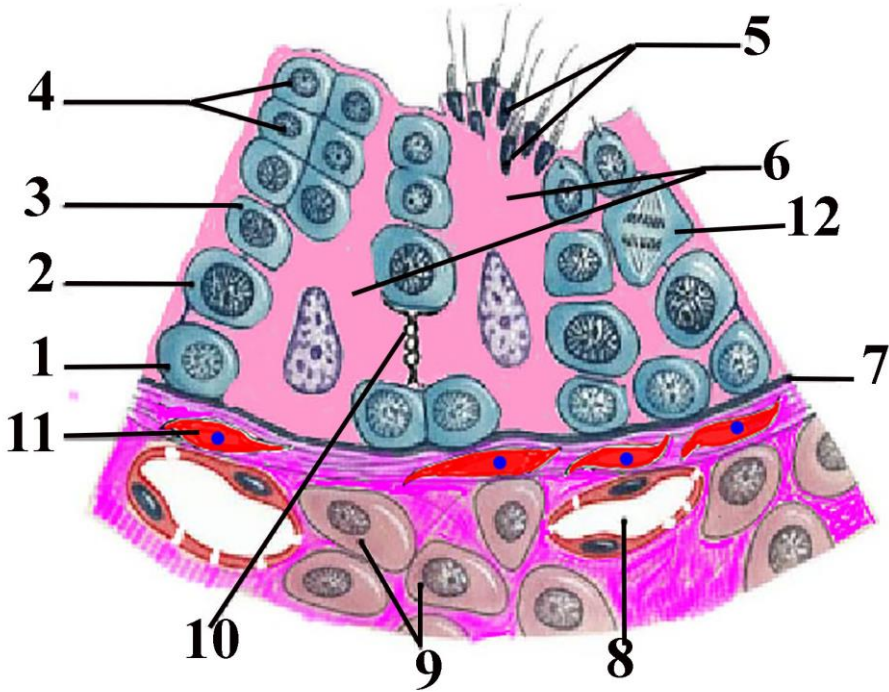
**Şəkil 32.2.**

**Рисунок 32.2.**

**Figure 32.2.**

**Photomicrograph of seminiferous tubule.**

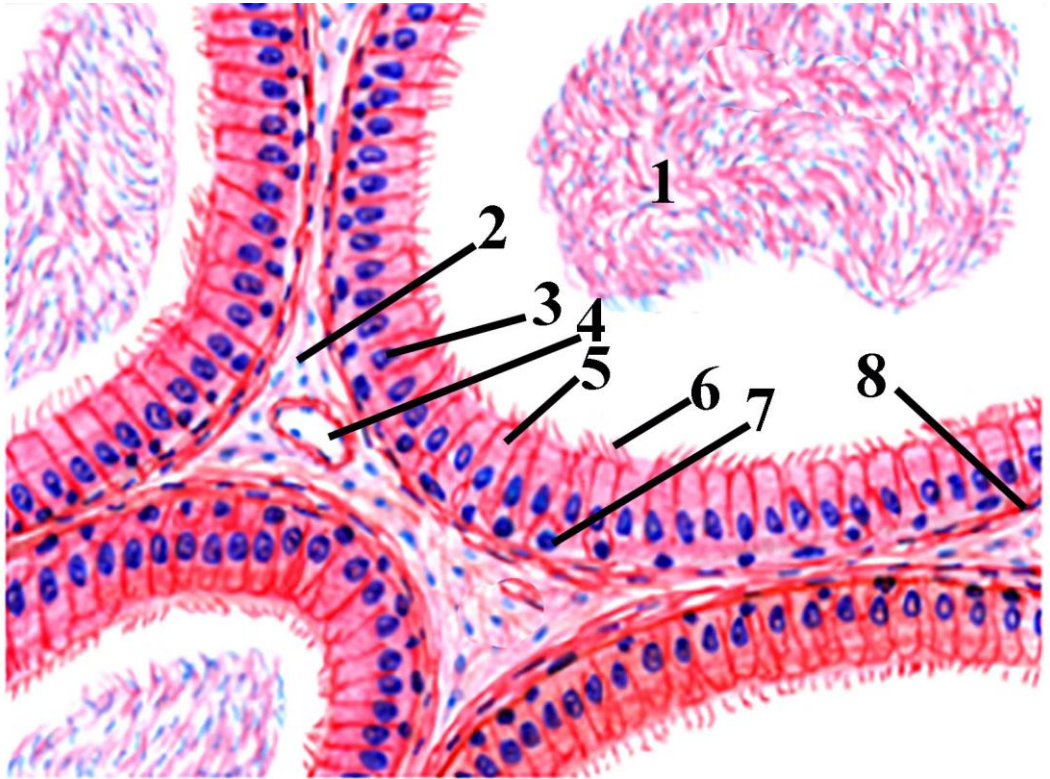
1. Myoepithelial cell
2. Pale type A spermatogonia
3. Nucleus of Sertoli cells
4. Type B spermatogonia
5. Primary spermatocytes
6. Early spermatids
7. Residual bodies (separated particles from spermatids during cytotomy).



**Şəkil 32.3. Рисунок 32.3. Figure 32.3.**  
**Schematic drawing of seminiferous tubule and surrounded it structures.**

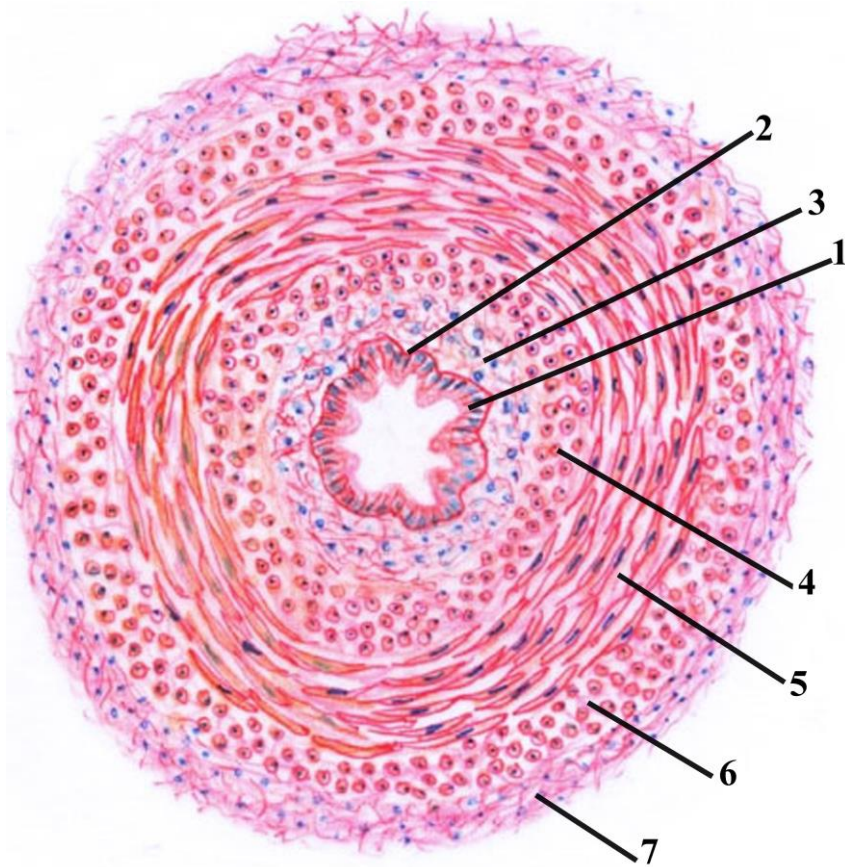
1. Spermatogonia
2. Primary spermatocyte
3. Secondary spermatocyte
4. Spermatids
5. Spermatozoa
6. Cytoplasm of Sertoli cell
7. Basal membrane
8. Capillary with fenestrated endothelium
9. Leydig cell
10. Tight junctions between Sertoli cells
11. Myoepithelial cell
- 12 spermatocyte in anaphase stage





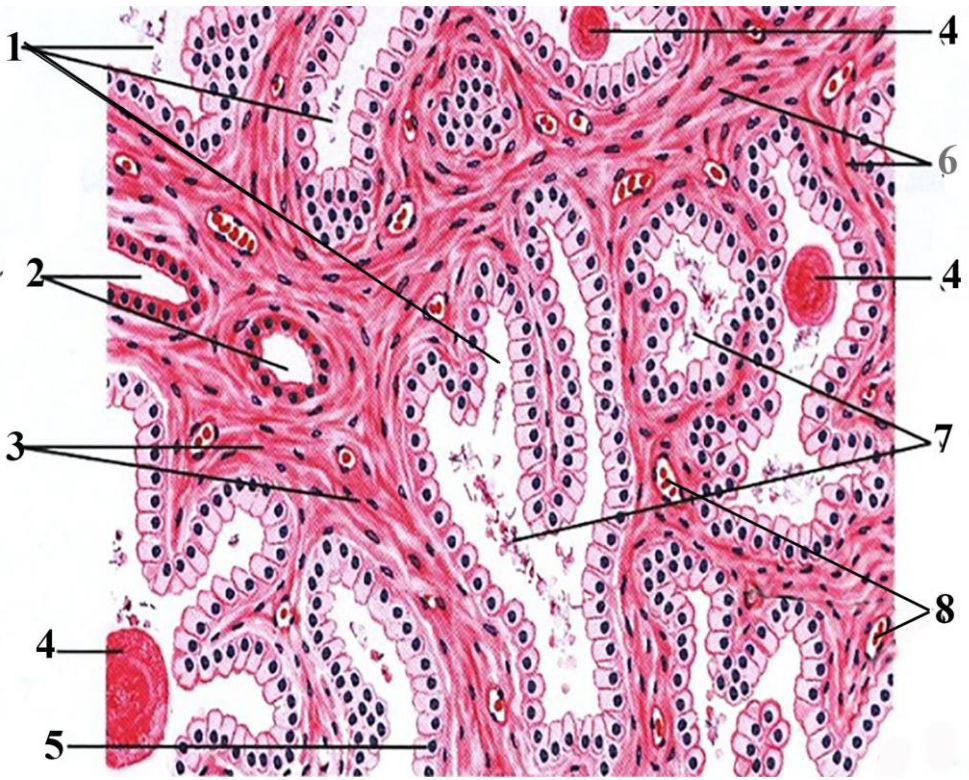
**Şəkil 33.1. Рисунок 33.1. Figure 33.1.**  
**Schematic representation of histological structure of duct of epididymis.**

1. Lumen filled with sperm cells
2. Connective tissue between ducts
3. Nucleus of the columnar epithelial cell
4. Blood vessel
5. Cytoplasm of the columnar epithelial cell
6. Stereocilia of the columnar epithelial cell
7. Nucleus of basal epithelial cell
8. Smooth muscle cells



**Şəkil 33.2.                    Рисунок 33.2.                    Figure 33.2.**  
**Schematic representation of transitional section of ductus deferens.**

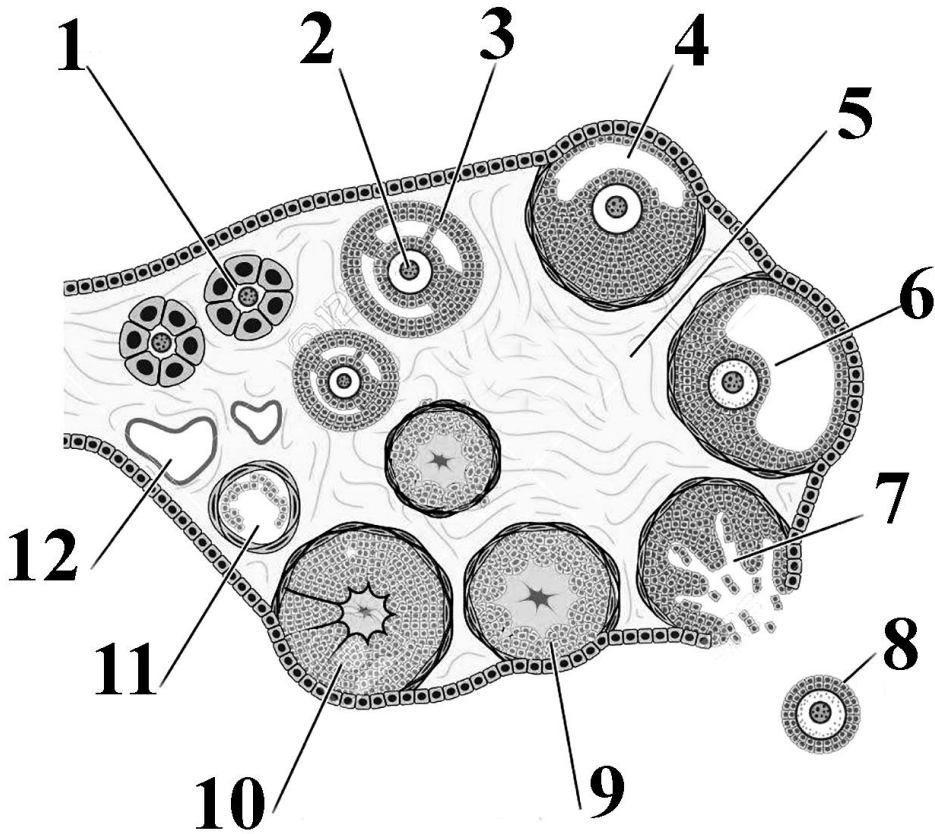
1. Two layers of epithelial cells of mucosa of ductus deferens
2. Basal membrane
3. Lamina propria
4. Internal longitudinal layer of muscularis externa
5. Middle circular layer of muscularis externa
6. External longitudinal layer of muscularis externa
7. Connective tissue(adventitia) layer



**Şakil 33.3.                      Рисунок 33.3.                      Figure 33.3**  
**Schematic drawing of structure elements of prostatic gland.**

- 1. Acini of gland
- 2. Prostatic ducts
- 3- 6. Fibromuscular elastic stroma
- 4. Prostatic concretions(corpora amylacea)
- 5. Prostatic epithelium
- 7. Prostatic secret (juice)
- 8. Blood vessels





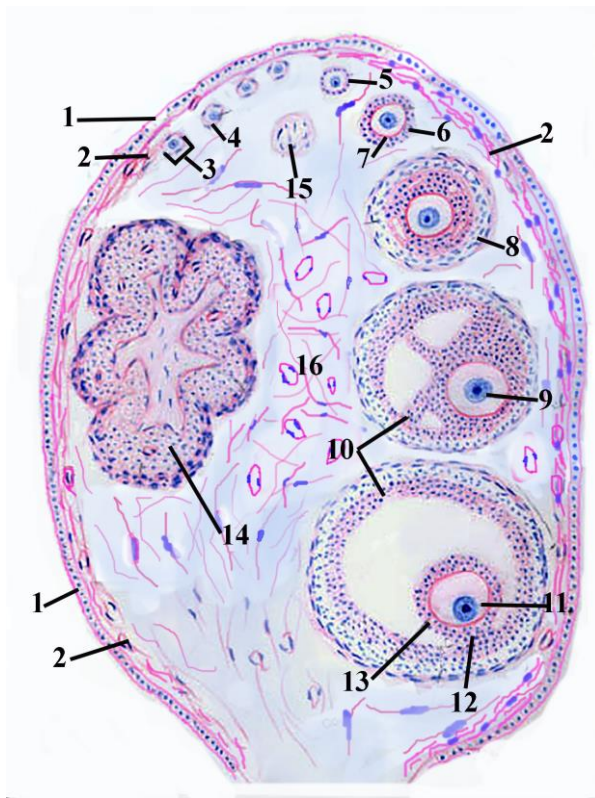
Şəkil 34.1.

Рисунок 34.1.

Figure 34.1.

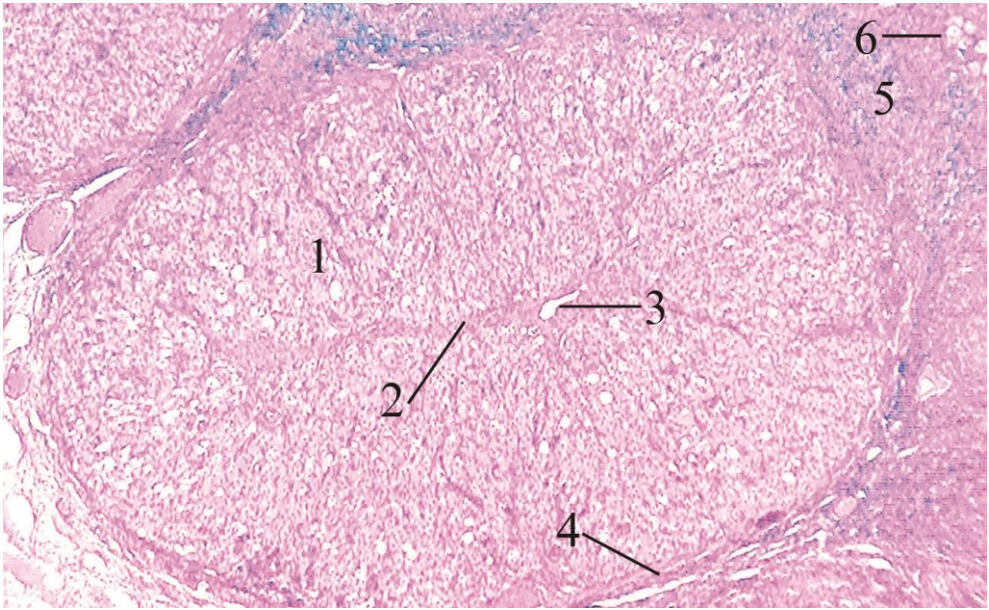
## Schematic representation of structure of ovary

1. Primary ovarian follicle
2. Primary oocyte
3. Secondary ovarian follicle
4. Lumen of antral follicle
5. Stroma of ovary
6. Secondary oocyte of mature follicle (Graafian)
7. Ruptured follicle
8. Secondary oocyte
9. Early corpus luteum
10. Formed corpus luteum
11. Atretic follicle
12. Corpus albicans



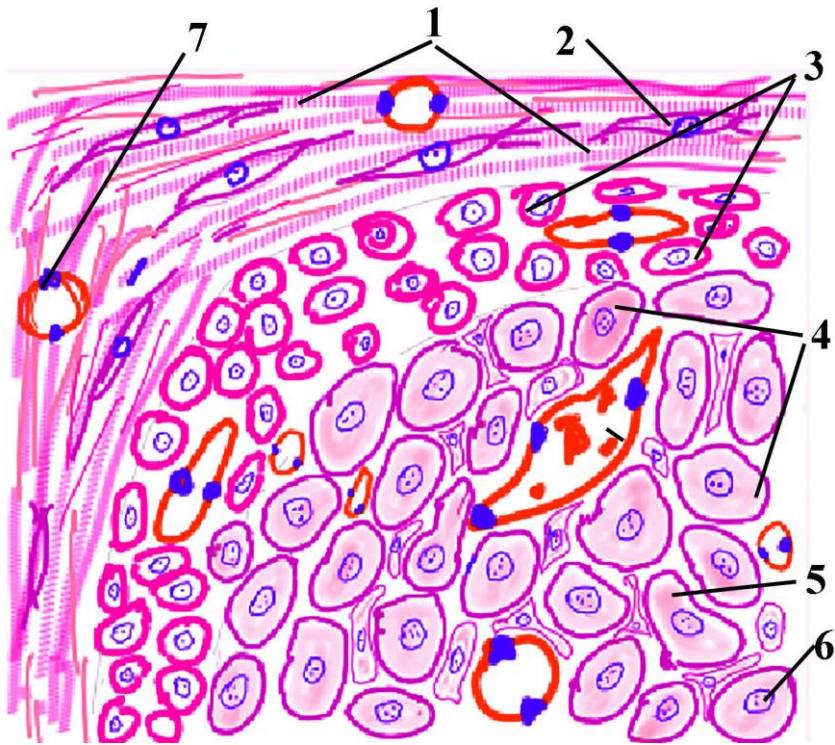
**Şəkil 34.2.                      Рисунок 34.2.                      Figure 34.2.**  
**Schematic drawing of structure of ovary.**

1. Ovarian mesothelium. Surface epithelium
2. Tunica albuginea
3. Primordial ovarian follicle
4. Simple squamous epithelium of primordial follicle
5. Primary ovarian follicle covered with simple cuboidal epithelium
6. Primary ovarian follicle covered with stratified cuboidal epithelium
7. Zona pellucida
8. Secondary follicle with theca coat
9. Primary oocyte of the tertiary(antral) ovarian follicle
10. Zona granulosa
11. Secondary oocyte of the mature ovarian follicle
12. Cumulus oophorus containing the oocyte
13. Corona radiata
14. Corpus luteum
15. Atretic follicle
16. Ovarian medulla



**Şəkil 34.3.            Рисунок 34.3.            Figure 34.3.**  
**Histological structure of corpus luteum of pregnancy.**

1. Granulosa-lutein cells
2. Septa of theca interna
3. Vein
4. Teca-lutein cells
5. Connective tissue of theca follicle; Tunica of follicle
6. Primordial follicle.



**Şəkil 34.4.**

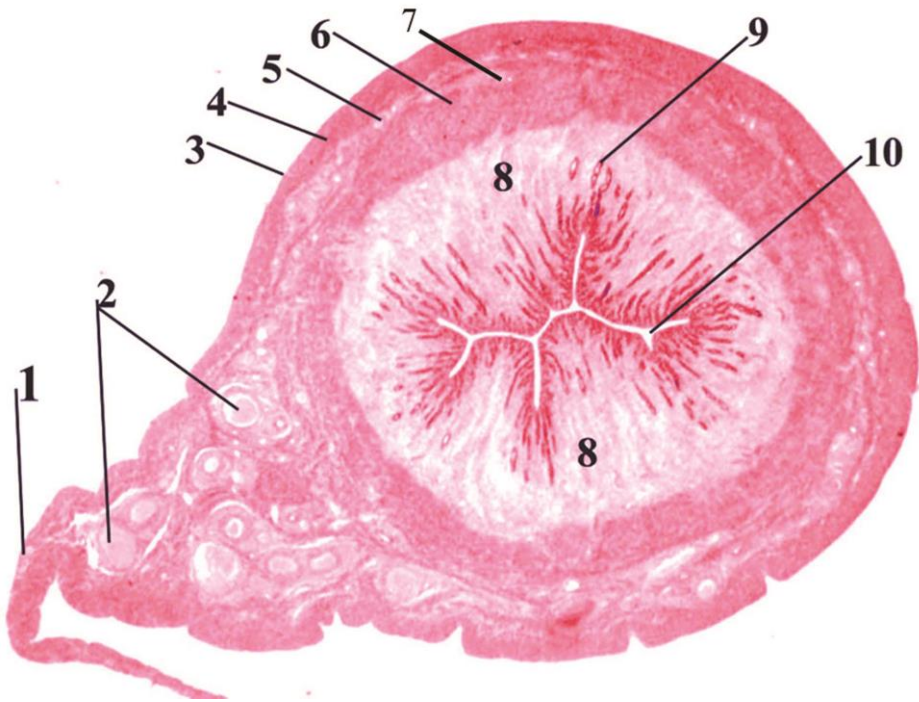
**Рисунок 34.4.**

**Figure 34.4.**

**Schematic drawing of structure of corpus luteum of pregnancy.**

1. Connective tissue elements of theca externa
2. Fibrocyte
3. Lutein cells of theca interna
4. Granulosa lutein cells
5. Cytoplasm of granulosa lutein cells
6. Nucleus of granulosa lutein cells
7. Vessel of theca externa





Şəkil 35.1.


Рисунок 35.1.

Figure 35.1.

**Histological structure of cat uterus.**

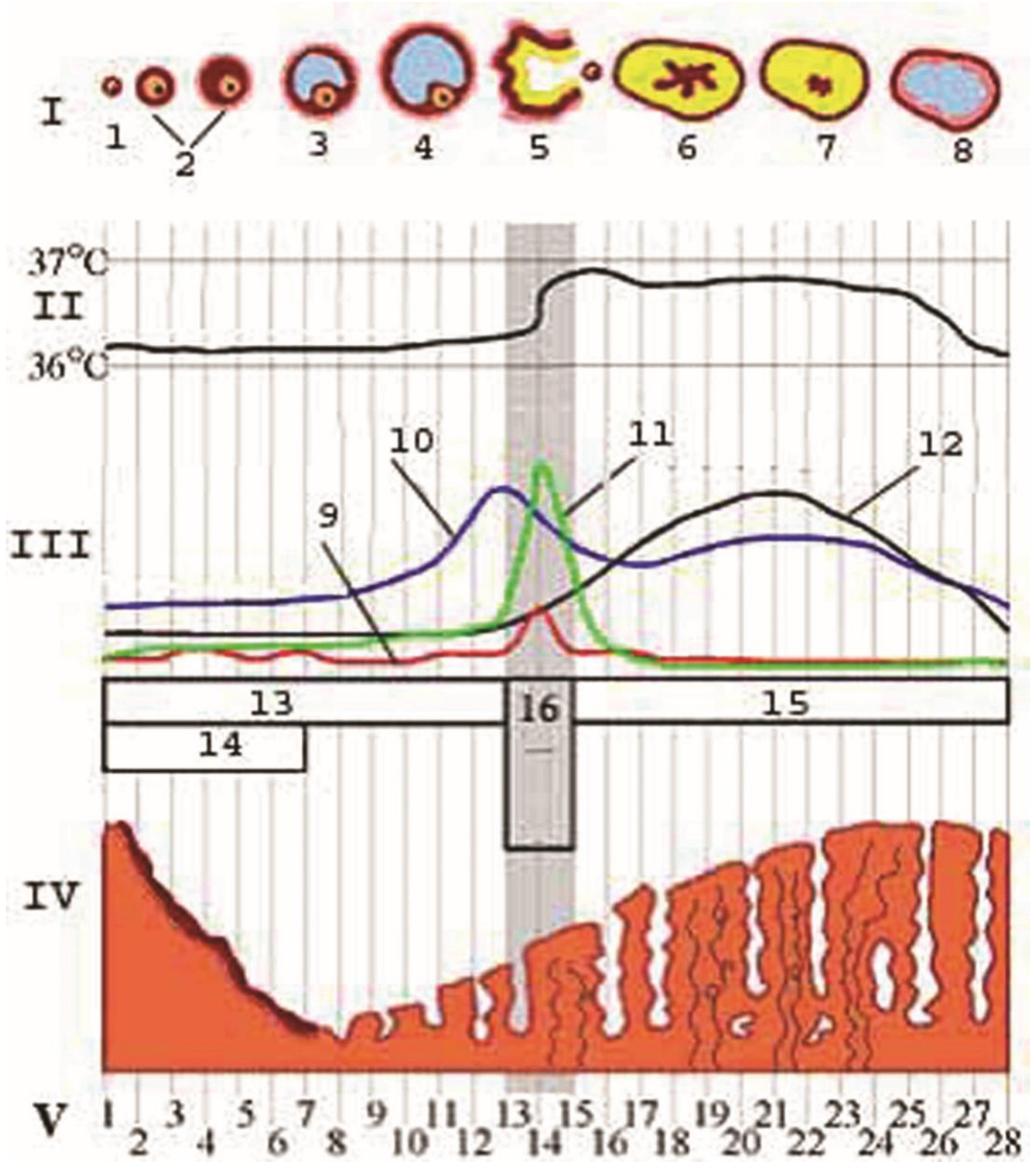
1. Broad ligament
2. Neurovascular bundle
3. Tunica
4. Supravascular(external) layer of myometrium
5. Vascular layer of myometrium
6. Submucosal layer of myometrium
7. Large diameter arteries and veins
8. Endometrial stroma, lamina propria
9. Uterine gland
10. Uterine cavity





**Şəkil 35.2.                      Рисунок 35.2.                      Figure 35.2.**  
**Schematic representation of structures of wall of uterus.**

1. Serosa (Perimetrium)
2. Muscular layer(Myometrium)
3. Mucosa of fundus of uterus (Endometrium)
4. Submuscular(internal) layer of myometrium
5. Supravascular(external) layer of myometrium
6. Basal layer of endometrium
7. Functional layer of endometrium; Spongy layer
8. Mesothelium of perimetrium
9. Connective tissue layer of perimetrium
10. Vascular(middle) layer of myometrium
11. Helical artery
12. Ciliated epithelium
13. Secretory cells of uterine
14. Stromal cells
15. Granular cells (Natural cells; NK cells)
16. Collecting venous lacuna



**Şəkil 36.1.****Рисунок 36.1.****Figure 36.1.****Schematic diagram of cyclic changes occurred on each lunar month in woman organism.**

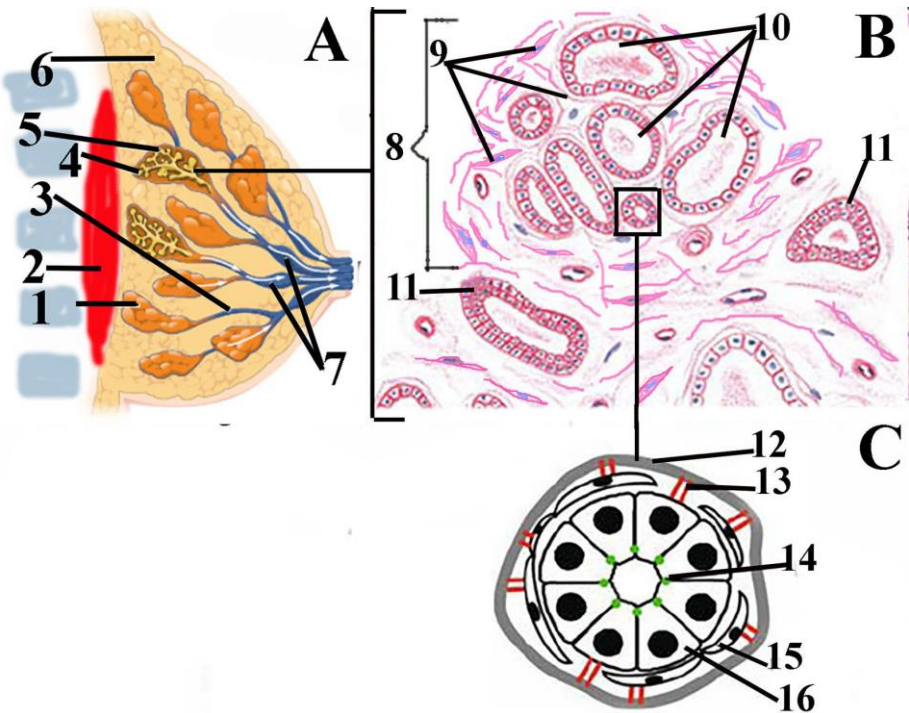
I. Consistently pictures of changes occurred in ovarian follicle.

1. primordial follicle; 2. primary follicle(in left),secondary follicle(in right); 3.tertiary follicle; 4.mature follicle; 5.ovulation; 6. corpus rubrum; 7. corpus luteum; 8. Degenerated corpus luteum.

II. Body temperature; III. Quantitatively changes of hormones.

9. follicle stimulating hormone; 10. estradiol; 11. luteinizing hormone; 12. progesteron; 13. Follicular phase; 14. menstruation; 15. luteal phase; 16. ovulation.

IV. Schematic pictures of histology of changes in endometrium; V.lunar month days.



**Şakil 36.2. Рисунок 36.2. Figure 36.2.**  
**Schematic drawing of anatomical(A),histological(B) and ultrastructural structure of mammary gland.**

**A**

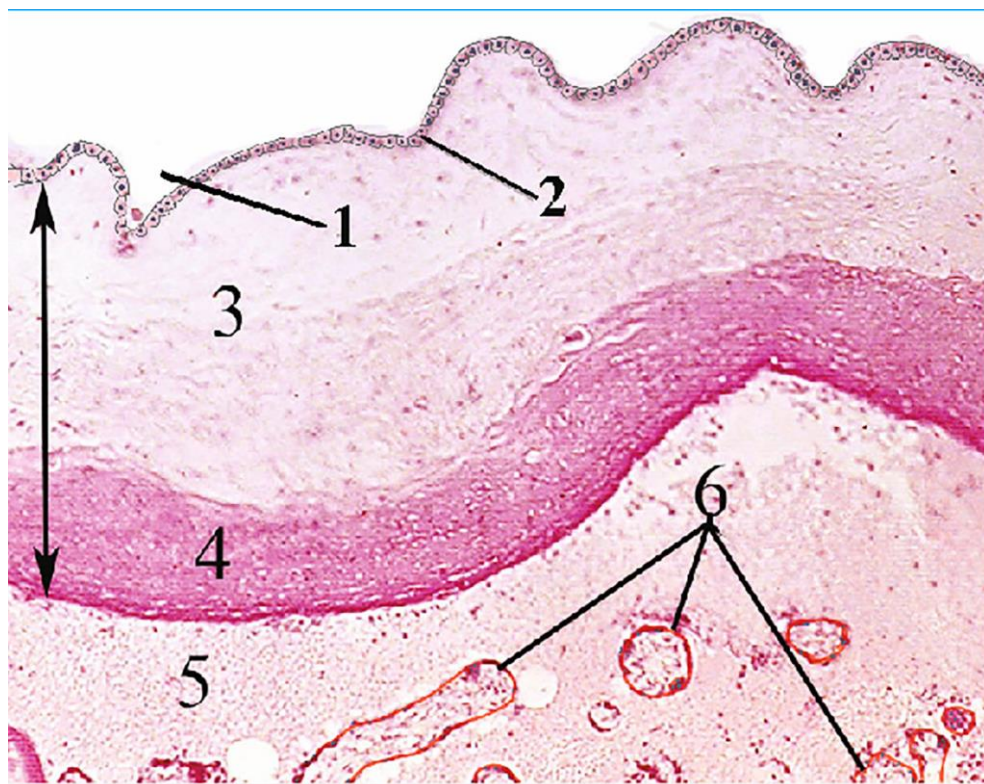
1. Lobe of mammary
2. Muscle of pectoralis major
3. Lobar duct
4. Acini of the lactating mammary gland
5. Connective tissue elements surrounded acini
6. Adipose tissue
7. Lactiferous sinus

**B.**

8. Lobule of the lactating mammary gland
9. Connective tissue elements
10. Acini of the lobule
11. Interlobular ducts

**C**

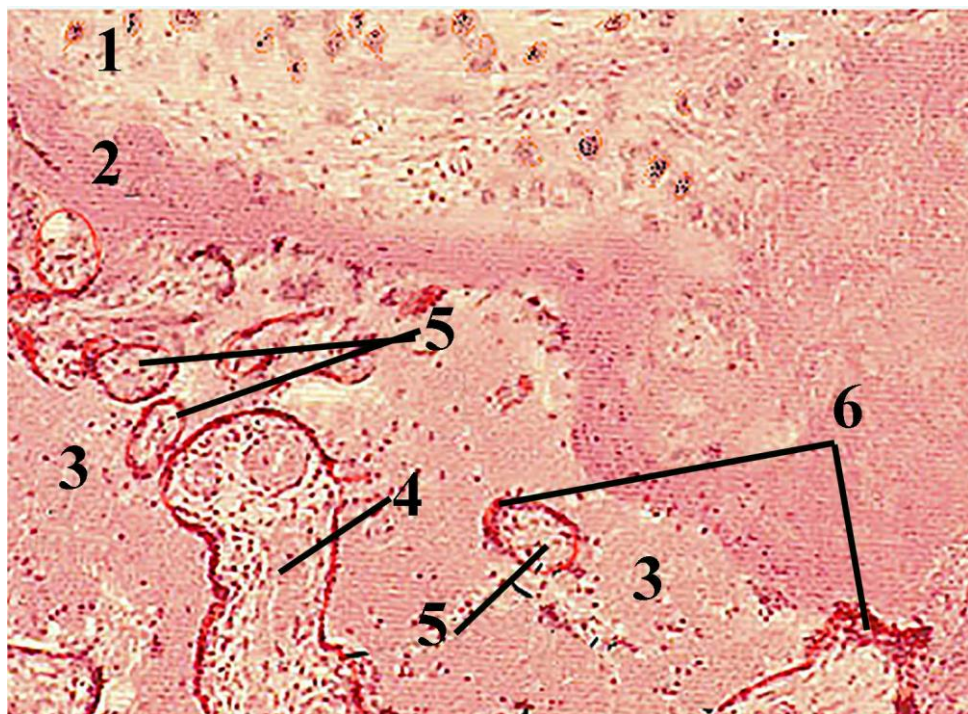
12. Basal membrane
13. Hemidesmosom
14. Tight junction between epithelial cells
15. Myoepithelial cell
16. Epithelial cell of mammary gland



**Şəkil 37.1.      Рисунок 37.1.      Figure 37.1.**  
**Microscopic structure of fetal part of placenta.**

1. Amnion cavity (filled with fluid)
2. Amniotic epithelium
3. Lamina propria of amnion
4. Fibrinoid layer
5. Intervillous spaces
6. Tertiary villi





**Şəkil 37.2.            Рисунок 37.2.            Figure 37.2.**  
**Histological structure of maternal part of placenta.**  
 1. Smooth muscle cells of myometrium  
 2. Decidua basalis  
 3. Intervillous spaces  
 4. Secondary villi  
 5. Tertiary villi  
 6. Accumulation place of nuclei of syncytiotrophoblasts-syncytial granules

## Referat için

## Referat için

## Referat için

## Referat için



## **Referat için**

## Dərs vəsaitinin tərtibi zamanı istifadə olunmuş

### ədəbiyyatların

### S İ Y A H I S I :

1. “Anatomik terminalogiya”. /prof. V.B.Şadlinskiyin redaktəsi ilə/. – Bakı ”Zərdabi LTD” MMC, Bakı. 2009. – 280с.
2. Balakişiyev K.Ə. Anatomik nomenklatura. Az. Döv. tədris-pedaqoji ədəbiyyatı nəşriyyatı. Bakı, 1964, 271 s.
3. Qasımov E.K. Sitologiya. Bakı, Azərnəşr, 2009, 183 s.
4. Алмазов И.В., Сутулов Л.С. Атлас по гистологии и эмбриологии. Москва, изд. "Медицина". 1978, 543 с.
5. Гистология, цитология и эмбриология: Атлас. Под ред. О.В.Вольковой и Ю.К.Елецкого. М.: Медицина, 1996, 544с.
6. Кахал С.Р. Автобиография. М.: Медицина, 1985, 270 с.
7. Terminologia Histologica. Международные термины по цитологии и гистологии человека с официальным списком русских эквивалентов / под. Ред. В.В.Банина и В.Л.Быкова. – М.: ГЭОТАР-Медиа, 2009. – 272 с.
8. Хэм А., Кормак Д. Гистология. IV том. Под ред. Ю.И.Афанасьева, Ю.С.Ченцова. Москва, "Мир" 1982, 242 с.
9. Caseci T. Doctor C's On-Line Histology. <http://www.doctorc.net/Labs/labtoc.htm>
10. Carola R., Harley J.P., Noback C.R. Human Anatomy. New York. San Frasko, Toronto. McCraw-Hill. Inc. 1992, 697 p.
11. Cormack DH. Essential histology. J.B.Lippincott Company. Toronto, Canada, 1993, 430 p.
12. Eroschenko VP. diFiores Atlas of Histology with Functional Correlations. Lippincott Williams and Wilkins. USA, 2005, 448 p.
13. Gartner LP, Hiatt JL. Color textbook of histology. 2<sup>nd</sup> ed. W.B.Saunders Company. Philadelphia London New York, 2001, 577 p.
14. Gray`s anatomy. 39<sup>th</sup> ed. Editor-in-chif Susan Standring. Elsevier Ltd, USA 2005, 1627 p.

15. Junqueira LC, Carneiro J. Basic histology. McGraw Hill Companies. New-York, Chicago, 2003, 515 p.
16. Kerr JB. Atlas of functional histology. Mosby, London St Louis Philadelphia Sydney Tokyo, 1999, 402 p.
17. Histology drawings.  
<https://histologydrawings.blogspot.com/p/book-recom.html>
18. Putz R. and Pabst R. Sobotta Atlas of Human Anatomy. Baltimore, London, Tokiyo. Williams & Wilkins, 1993, v1, 419 p.
19. Ross M.H., Pawlina W. Histology: a text and atlas: with correlated cell and molecular biology. 6th ed.. Lippincott Williams & Wilkins, 2015, P. 974.

## MÜNDƏRİCAT

<b>Ön söz</b>	<b>3</b>
<b>Mövzu 1. Onurğa beyni. Beyin qişaları</b>	<b>6</b>
<b>Mövzu 2. Onurğa beyni düyünü. Periferik sinir kötüyünün quruluşu. Vegetativ sinir sistemi.....</b>	<b>9</b>
<b>Mövzu 3. Baş beyin kötüyü. Beyincik.....</b>	<b>11</b>
<b>Mövzu 4. Baş beyin yarımkürələri qabığı. Modul. ....</b>	<b>13</b>
<b>Mövzu 5. Görmə üzvü. Qoxu üzvü.....</b>	<b>16</b>
<b>Mövzu 6. Eşitmə və müvazinət üzvləri. Dad üzvü.....</b>	<b>19</b>
<b>Mövzu 7. Hipotalamus. Hipofiz. Epifiz. ....</b>	<b>22</b>
<b>Mövzu 8. Qalxanabənzər və qalxanabənzərətraf vəzilər. .</b>	<b>24</b>
<b>Mövzu 9. Böyrəküstü vəzilər. ...</b>	<b>27</b>
<b>Mövzu 10. Arteriyalar.....</b>	<b>28</b>
<b>Mövzu 11. Mikrosirkulyator yataq damarları</b>	<b>31</b>
<b>Mövzu 12. Venalar. Limfa damarları.....</b>	<b>34</b>
<b>Mövzu 13. Ürək.....</b>	<b>36</b>
<b>Mövzu 15. Qırmızı sümük iliyi. Qanyaranm.....</b>	<b>39</b>
<b>Mövzu 16. Timus (çəngələbənzər vəzi.....</b>	<b>40</b>
<b>Mövzu 17. Limfa düyünü. Dalaq...</b>	<b>42</b>
<b>Mövzu 18. Dodaqlar. Damaqlar. Yanaqlar. Dil...</b>	<b>45</b>
<b>Mövzu 19. Dişlər.....</b>	<b>48</b>
<b>Mövzu 20. Ağız suyu vəziləri. Limfoepitelial halqa. Damaq badamları...</b>	<b>50</b>
<b>Mövzu 21. Qida borusu. Mədə...</b>	<b>53</b>
<b>Mövzu 22. Nazik bağırsaq,yoğun bağırsaq.Soxulcanabənzər çıxıntı(appendiks) ..</b>	<b>57</b>
<b>Mövzu 23. Qaraciyər</b>	<b>61</b>
<b>Mövzu 24. Mədəaltı vəzi....</b>	<b>65</b>
<b>Mövzu 25. Burun boşluğu. Qırtlaq. Traxeya.....</b>	<b>67</b>
<b>Mövzu 26. Bronxlar. Ağciyərlər .....</b>	<b>68</b>
<b>Mövzu 28. Dəri.....</b>	<b>77</b>

- Mövzu 29. Dəri törəmələri...79**  
**Mövzu 30. Böyrəklər ...83**  
**Mövzu 31. Sidik çıxarıcı yollar...88**  
**Mövzu 32. Toxumluq (xayalar). Spermatogenez... 90**  
**Mövzu 33. Xaya artımı. Toxumçıxarıcı yollar. Prostat vəzi 93**  
**Mövzu 34. Yumurtalıqlar. Ovogenez 95**  
**Mövzu 35. Uşaqılıq boruları. Uşaqılıq. Uşaqılıq yolu...98**  
**Mövzu 36. Cinsiyyət tsikli. Süd vəziləri...100**  
**Mövzu 37. Cift ... 102**  
**Ədəbiyyat siyahısı..... 109**

**Qasimov Eldar Köçəri oğlu**

Tibb elmləri doktoru, professor, Azərbaycan Tibb Universitetinin  
Histologiya, embriologiya və sitologiya kafedrasının müdiri

**Xüsusi histologiya – sxemlər**



**Nəşriyyatın direktoru:**

**Mətbəənin direktoru:**

**Rəssam: Səmədov H.A.**

**Kompüter yığıcı və dizayn: Hüseynova V.M.**